

**PRACTICAL MANUAL  
OF  
VETERINARY ANATOMY**

(B.V.Sc. & A.H. FIRST PROFESSIONAL YEAR 2023-24)

**Volume I (Unit- I, II, III)**



**DEPARTMENT OF VETERINARY ANATOMY & HISTOLOGY**

**MJF COLLEGE OF VETERINARY & ANIMAL SCIENCES,**

**CHOMU, JAIPUR (RAJASTHAN)**



**PRACTICAL MANUAL**  
**IN**  
**VETERINARY ANATOMY**

<b>NAME:</b> .....
<b>ROLL No. :</b> .....
<b>Batch:</b> .....

1<sup>st</sup> Year B.V. Sc. & A.H. (2023 - 24)

**DEPARTMENT OF VETERINARY ANATOMY & HISTOLOGY**  
**MJF COLLEGE OF VETERINARY & ANIMAL SCIENCES,**  
**CHOMU, JAIPUR (RAJASTHAN)**



## **CERTIFICATE**

This is to be certify that Mr. /Ms. ....  
..... Roll. No.....of First year B.V.Sc &  
A.H. has successfully completed all practicals in Veterinary Anatomy during first  
year of the academic year .....

Date :

Place :

**Signature of Head of Department**

**Signature of Course Teacher**



## **FOREWORD**

I am very happy to go through the Practical Manual entitled “Veterinary Anatomy” Department of Veterinary Anatomy & Histology, MJF College of Veterinary & Animal Sciences, Chomu, Jaipur (RAJ.) The Manual covers the practical syllabus of undergraduate course (Veterinary Anatomy, Volume I) prescribed by Veterinary Council of India (MSVE 2016) for B.V.Sc & A.H. programme.

The Manual is a good attempt and is based on cumulative experience of teaching undergraduate courses. The language used in the manual is simple and lucid. The outline and description of practical exercises covering objectives, materials required, procedures and observations to be taken have been nicely presented which would be helpful in conducting practicals more effectively.

I hope this manual will make its own place in the libraries of Veterinary and Animal Science Colleges/Universities and various Livestock Institutions in near future.

I congratulate the authors for the efforts put in bringing out this practical manual.

**Dean**  
MJF College of Veterinary &  
Animal sciences, Chomu, Jaipur





## **ACKNOWLEDGEMENT**

Ever since the introduction of new course for professional B. V. Sc. & A.H. degree programme under Veterinary Council of India pattern in Veterinary Colleges/Universities in the country, there was a dire need to have a practical manual on Veterinary Anatomy subject which covers the practical syllabus of undergraduate (Veterinary Anatomy) This new course was not independently developed in most of the Veterinary College/University before the introduction of Veterinary Council of India programme (MSVE 2016). The present manual covers the practicals with objectives, material required, procedure, steps to follow, precautions to be taken, observations to be recorded and exercise to be done by the students. We hope that users will find the manual immensely useful.

We look forward to receive the valuable suggestions of users for improvement of this manual



# INDEX

## UNIT I

S.No.	Title	Page No.	Date	Signature





# UNIT I

## Practical No. 1

**To get familiarized with the topographic and descriptive terms used in anatomy and to study anatomical planes**

1. **Anatomy** (Ana=apart; Tomy=cutting) Detailed structure studied by dissection.
2. **Veterinary Anatomy**:-Comparative Anatomy/ Form and structure of principal domesticated animals studied on the basis of comparison with ox.
3. **Topographic Anatomy**:-Study of anatomy of organs in relation to surrounding structures in order to describe its location and position.
4. **Systemic Anatomy**: - Body is comprised of a number of organs grouped into different system: e.g. Digestive system, respiratory system, etc.

### **Divisions of Systemic Anatomy:**

1. **Osteology:**
2. **Arthrology:**
3. **Myology:**
4. **Splanchnology:**
5. **Angiology:**
6. **Neurology:**
7. **Aesthesiology:**

### **Topographic Terms:**

1. **Ventral /inferior**:-The surface directing towards the plane of support is termed as ventral.
2. **Dorsal /Superior**: - The surface directing upwards is termed as dorsal.
3. **Median plan**: - The plan divides the body into two equal halves.
4. **Sagittal plan**: - The plane parallel to the median plane.
5. **Transverse/Segmental plane**:-The plane cutting the long axis of the body perpendicular to the median plane.
6. **Frontal plane**:-The plane that is perpendicular to the median and transverse plane.

7. **Medial surface:**-A structure or surface which is nearer to the median plane is known as medial/ internal surface.
8. **Lateral surface:**-A structure or surface which is away from the median plane is termed as lateral surface.
9. **Anterior/Cranial/Rostral/Oral/Nasal:**-The head end of the body is termed as cranial.
10. **Posterior/ caudal / aboral:** - The tail end is known as caudal.
11. **Coronal plane:**-Any plane which is at right angle to Sagittal plane.

**Certain terms are used in a special sense as applied to the limbs:**

1. **Proximal and distal-** express relative distances of part from the long axis of the body.
2. The anterior face of the distal part of the limb is termed as **dorsal** whereas the posterior surface is known as **volar and plantar in the thoracic and pelvic limbs respectively.**
3. The terms **superficial and deep** are useful to indicate relative distances from the surface of the body.
4. **Axial:** - towards the central line of body
5. **Abaxial:** - away from axis.

**Descriptive terms used in Osteology:**

1. **Process:** a general term for prominence. e.g. anconeus process, olecranon process.
2. **Tuberosity:** a large, rounded non-articular projection e.g. radial tuberosity, tibial tuberosity.
3. **Trochanter:** a non-articular prominence e.g. trochanters of femur.
4. **Spine/ Spinous process:** a pointed projection e.g. scapular spine, supraspinous process.
5. **Crest:**-a sharp ridge like projection .e.g. facial crest, tibial crest.
6. **Line:**-a very small ridge like marking. e.g. muscular lines.
7. **Head:**-rounded articular enlargement at the end of a bone e.g. head of humerus and femur.
8. **Neck:**-constricted part below head.
9. **Condyle:** an articular somewhat cylindrical eminence e.g. condyles in humerus and femur. a non-articular projection in relation to a condyle is termed as **epicondyle.**
10. **Trochlea:**-a pulley like articular mass. e.g. femoral trochlea, tarsal trochlea.
11. **Glenoid cavity:** - a shallow articular depression. e.g. in scapula.
12. **Cotyloid cavity:** - a deep articular depression. e.g. in oscoxae-acetabulum.
13. **Fovea:**-an articular surface in the form of a very small pit.
14. **Fossa:** - a depression.
15. **Groove / sulci:** - Elongated depression.
16. **Incisura:** - a notch like depression.
17. **Cornu:** - curved horn like process.
18. **Tubercle:** - a small projection.
19. **Protuberance / prominence / tours:** - varieties of bony projection.

20. **Cleft:** - a fissure in a bone.
21. **Lamina:** - a thin plate like structure.
22. **Facet:**-the articular surface of small extent (not strongly convex or concave) is termed as facet. e.g articular facets of vertebrae, ribs etc.
23. **Foramen:** - it is a perforation for the transmission of vessels, nerves etc. e.g. various foramina of skull.
24. **Sinus:** - it is an air cavity within a bone or bones; it is lined with mucous membrane and communicates with the exterior.
25. **Epiphysis:**-a process of bone attached to another by cartilage which later ossifies.
26. **Diaphysis:** - the shaft of the long bone.
27. **Metaphysis:**-the end part of the diaphysis opposing epiphysis of the long bone.
28. **Medullary cavity:** - in the typical long bones the shaft is hollow, known as medullary cavity.
29. **Endosteum:** - is the thin fibrous membrane which lines the medullary cavity and the large Haversian canals.
30. **Periosteum:** - is the membrane which invests the outer surface of bone except where it is covered with cartilage.
31. **Hamulus:** - hook like process.

**SKELETON** includes all the harder, supportive and protecting structures. When it is situated externally, derived from ectoderm is known as Exoskeleton. e.g. Shells and chitinous coverings of invertebrates, scales of fishes, shield of turtles, and feather, hair, and hoofs of higher vertebrates. The skeleton, which is embedded in the soft tissue, and derived from the mesoderm or entoderm (primitive/axial skeleton), is known as **Endoskeleton**.

**Skeleton:** - The frame work of hard structures which support and protects the soft tissues of the body. The endoskeleton.

1. **Axial skeleton:** - it consists of skull, vertebral column, ribs and sternum
2. **Appendicular Skeleton:** - It consists of bones of the limbs.
3. **Splanchnic/visceral skeleton:** - It consists of certain bones developed in the viscera or soft organ. e.g. os penis of dog, os cordis of ox, os phrenic of camel, entoglossal bone of the fowl, etc.

### **Classification of bones:**

Bones are classified according to their shape and function. These are mainly divided into seven classes:-

- i) **Long Bones:**-Each bone has a shaft (diaphysis) and two extremities (epiphysis). The shaft encloses the medullary cavity. These act as lever. e.g. radius, femur, humerus etc.



- ii) **Short Bones:**-These bones are somewhat similar in length, width and thickness. Their main function is to diffuse the concussion e.g. carpus, tarsus and sesamoid bones.
- iii) **Flat Bones:**-These bones expanded in both the directions and furnish sufficient area for the attachment of muscles and afford protection to the organs which they cover. e.g. scapula and oscoxae. Flat bones are composed of two plates of compact bone with intervening spongy bone. The intervening spongy tissue in the bones of cranial vault is called as diploe e.g. scapula, some cranial bones of skull.
- iv) **Irregular Bones:** - These are irregular in shape and perform various functions. These are usually median and unpaired e.g. vertebrae.
- v) **Pneumatic Bones:** - are found in the skeleton of birds. They are lined by mucous membrane and communicate with the respiratory system. Air containing cavities (sinuses) of skull are also serving the same purpose.
- vi) **Sessamoid bones:**-These are small seed like bones, developed within tendon. They work as pulley to avoid friction e.g. patella.
- vii) **Visceral bones:** - These bones are found in the viscera of small animals and birds e.g. os penis in dog, os cordis in ruminant, osopticus in fowl, os phrenic of camel & Entoglossal bone of the fowl.

**Cartilage:** Non vascular pliable strong structures form supporting frame work of articulating surfaces of bones, foetal skeleton and certain organs of the body. Cartilage is composed of a semihard matrix of sulphated glycoaminoglycans embedded with collagenous or elastic fibres and cartilage cells – chondrocytes. There are three types of cartilage i.e. hyaline cartilage, elastic and fibro cartilages e.g elastic cartilages are found in epiglottis and external ear

### To study the preparation of bones

#### **Collection and Preparation of bones for osteological study:**

1. The Bones are collected from any carcass & prepared for study.
2. Always use the bones of adult animals are suitable for study as that of young ones as they are prone to disintegration.
3. The skin and the possible amount of flesh adhering to bones should be removed by knives; such bones are called wet bones.
4. Disarticulate the whole Skelton Pedal bones are to left with hoof.
5. In case of skull, mandible should be detached and mouth parts removed. Tongue should be separated carefully to keep the hyoid bone intact.
6. The brain should be lacerated with a stick through foramen magnum & possible contents removed.
7. Eye balls should be extirpated.
8. The nasal cavity should be left untouched.
9. Now the bones are ready for maceration.

### **Process of Maceration:**

1. Wet bones are macerated to get rid of the animal matter adhering to them.
2. It can be achieved by burying them at the depth of not less than two feet. But this is possible only in areas of dry climate and fine weather. Cover the grave with a flat stone so as to avoid the digging by carnivore animals.
3. This method is useful under field conditions where other facilities are not available. When bones are required at quick interval, wet bones are boiled in a big container on slow fire. The cooked flesh is removed as it collects on the top. But this process takes hours of boiling and depends upon size of bones and amount of adhering flesh.
4. After preliminary boiling the bones are scraped with a blunt knife and scrubbed with a dandy brush.
5. Bones are then steeped overnight in water to which lime is added and reboiled next day with soap for short time.

### **For general osteological work:**

1. Bones are steeped in coldwater and left over for days in a container with lid. By this process the tissue adhering to the bones get purified.
2. Tissues are detached slowly and collected at top, summer is suitable for this purpose, It takes a month for bones to clear.
3. The water of container is changed at weekly intervals.
4. The bones are periodically examined and sheds of tissue are scraped and brushed.
5. At last lime should be added to water.
6. All the bones do not take equal time for maceration.
7. Finally the bones should be thoroughly rinsed in cold water and then spread out in sunlight for drying.
8. During this stage the bone marrow oozes out of the nutrient foramen and Haversian canals. They should be periodically cleaned by a dry piece of cloth.
9. When fat and marrow cease to ooze, final rinsing and indoor drying will prepares the bones, called macerated bones.
10. Bones may be kept in racks or articulated occasionally dusted with insecticides
11. A coat of varnish should be given for a finishing touch. It will remove all traces of smell.
12. Macerated bones can be kept in good condition for years. Mounted skeletons are highly useful for studies in situ, while spare bones are suited for identification and detailed study

- EXERCISE:**
1. Draw an object and show different planes/ directions / surfaces etc.
  2. Draw the sagittal section of long bone and label all the structures.





## Practical No. 2

### Study of boundaries of thoracic, abdominal and pelvic cavities

#### Thoracic cavity:

The thoracic cavity is the intermediate in size among the three body cavities. It is in the form of a short, hollow cone, slightly constricted laterally. Its base is cut off obliquely by the diaphragm. This cavity contains the lungs, pericardium and heart, thoracic portion of oesophagus and trachea, large arterial, venous and lymphatic trunks, nerves and lymphatic vessels and glands. In the young animals, it also contains the thoracic portions of the thymus. Its roof is formed by the thoracic vertebrae, and the thoracic muscles along with their ligaments. Lateral walls are formed by the ribs and the inter-costal muscles. The floor is constituted by the sternum, cartilages of the sternal ribs and the muscles connected with these. The posterior wall is formed by the convexity of the diaphragm.

The apex or inlet on the entrance to the thorax is oval, small and vertically elongated. This is bounded dorsally by the first thoracic vertebra, laterally by the first pair of ribs and ventrally by the manubrium sterni. It is occupied by the axillary and carotid arteries with some of their branches, the vagus, sympathetic, recurrent laryngeal and the phrenic nerves, the trachea, the oesophagus, the longus colli and scalenus muscles partially and posterior cervical lymph nodes.

The base is represented by the thoracic outlet. It is bounded dorsally by the last thoracic vertebra, laterally by last few ribs and ventrally by the xiphoid cartilage. It is covered by diaphragm which separates the thoracic and abdominal cavities. The diaphragm presents three openings at its extreme convexity - the hiatus oesophagii, hiatus aorticus and foramen venae cavae through which the oesophagus, aorta and posterior vena cava pass through. The diaphragm is a major muscle of inspiration.

The thoracic cavity is lined by a loose layer of connective tissue called the endo-thoracic fascia which anchors the pleura to the lateral wall of thorax.

#### Pleura:

These are two thin, glistening, serous membranes which lined the thorax, called the left and the right pleura. Each of them pleurae consists again of two portions - parietal and visceral. In between these parietal and visceral sacs, the pleural sac exists which contains liquor pleurae.

The pleura cover the lungs and then is reflected on to the pericardium, thoracic wall and diaphragm. The part of pleura which covers the surface of the lung is called visceral layer or visceral pleura on pulmonary pleura, and that which lines the inner face of the thoracic walls and covers the diaphragm is the parietal layer. The space between these two layers is the pleural cavity or pleural sac. The two left and right pleura meet at the anterior part of the median line. The space located in between the two pleural sacs (right and left) is called **mediastinum**. This

space enclosed all the visceral organs contained in the thoracic cavity, except the lungs. The part of the pleura attached to the internal face of the ribs and the intercostal muscles is called the costal pleura, the part covering the thoracic face of the diaphragm is called the diaphragmatic pleura, the part covering the structures of the mediastinum is called mediastinal pleura and the part covering the pericardium is the pericardial pleura.

**Blood supply:** Intercostal, internal thoracic, musculo-phrenic, pericardial and bronchial arteries.

**Nerve supply:** Vagus (10th), sympathetic, phrenic and intercostal nerves.

### **Species differentiation**

**Horse:** The thoracic cavity is larger and more extensive in horse. The pleura is thin and the **posterior mediastinum is fenestrated**, allowing a communication between the two pleural sacs.

**Dog:** The thoracic cavity is proportionally larger and more capacious. Mediastinum is imperforated.

**Pig:** The lateral walls of the cavity are not as flat as they are in horse or ruminants. The cross-sectional outline of the cavity at its middle is more cylindrical. The endothoracic fascia and the pleurae are well developed. The two pleural sacs do not communicate through posterior mediastinum. The right pleural sac is considerably larger.

**Fowl:** The diaphragm is rudimentary, so the thoracic cavity continues posteriorly as abdominal cavity.

### **Abdominal and pelvic cavity and disposition of peritoneum**

#### **a. Abdominal cavity:**

It is the largest cavity in the body separated from the thoracic cavity by the diaphragm, and is continued posteriorly with the pelvic cavity. The line of demarcation between the abdominal and pelvic cavities is called the **pelvic brim**. The pelvic brim is formed dorsally by base of the sacrum, laterally by the ilio-pectineal line and anterior border of the pubis and centrally by the pubic bone. The abdominal cavity is ovoid and laterally compressed, which extends from the sternal part of diaphragm to the pelvic inlet.

#### **Boundaries of the abdominal cavity:**

The roof or dorsal border is formed by the lumbar vertebrae, muscles and lumbar part of the diaphragm. The lateral walls are formed by the oblique and transverse abdominal muscles and fascia. The floor or ventral wall is formed by the rectus abdominis muscle and the aponeurosis of the oblique and transverse abdominal muscles. The anterior wall is formed by the concavity of the diaphragm. The muscular (lateral) wall is lined by diaphragmatic; transverse, iliac and deep thoraco-lumbar fascial layers. The abdominal cavity contains the greater part of the

digestive and urinary organs, internal genital organs, blood vessels, lymph nodes, lymphatics, spleen, adrenal glands and foetal vestige.

The **flank** is that part of the lateral abdominal wall which is formed by soft tissue (free of osseous tissue). The triangular depression on its dorsal part is called **paralumber fossa** or **sublumber fossa**, which is bounded ventrally by the dorsal border of obliquus abdominis internus muscle, dorsally by the lateral border of longissimus dorsalis muscle and anteriorly by the last rib.

The abdominal wall in adult is pierced by six openings (three foramina of diaphragm one femoral ring for femoral and two openings inguinal canals). In fetus, there is one more opening called **umbilical opening** through which the urachus passes. The urachus connects the urinary bladder with allantois in fetus. The umbilical opening is closed after birth by fibrous time forming a scar called the umbilicus which is visible on ventral midline.

### **Species differentiation**

**Horse:** The abdominal cavity is long but less capacious. It is barrel-shaped. The flanks are not so hollow and the floor of the abdomen's more compact.

**Dog:** The abdomen is narrow and long.

#### **b. Pelvic cavity:**

It is the caudalmost and the smallest of the three cavities of the body. It's continuous in front with the abdominal cavity, the line of demarcation being the brim of the pelvic on the pelvic brim. It contains the rectum and parts of the internal genital and urinary organs.

#### **Boundaries of the pelvic cavity:**

The roof on dorsal wall is formed by the sacrum and first two coccygeal vertebrae. Lateral wall is formed by the ilio-pectineal line and sacro-tuberal ligament. The floor or ventral wall is formed by pubis and ischium. Pelvic outlet is formed dorsally by the third coccygeal vertebra, ventrally by ischial arch, posteriorly by sacro-tuberal ligament, the semimembranosus muscle, which encloses the perineum. The perineal region or perinum contains the anus root of the penis in male animals and vulva in female animals. The pelvic cavity is lined by pelvic fascia and peritoneum which is the continuation of the abdominal peritoneum.

#### **Peritoneum:**

The abdominal cavity is lined by peritoneum, which is a thin glistening slippery serous membrane and covers the viscera. The organs which are covered by the peritoneum are called as peritoneal organs, whereas uncovered organs are referred as retroperitoneal organs. In male, it is a completely closed sac, but in female, it has two openings of the fallopian tubes. It consists of two parts - visceral layer and parietal layer. The space between these two layers is called the peritoneal cavity which is filled with serous (peritoneal) fluid which acts as a lubricant. The fore

surface of this membrane is glistening and smooth, lined by mesothelial cells that produces the serous fluid. The peritoneal organs are covered by visceral layer of peritoneum. These organs are connected by the various folds formed by the peritoneum called as omentum, mesentery, ligaments etc. These folds also contain varying amounts of connective tissue, fat, lymph nodes, blood vessels, nerves and sometimes smooth muscle fibers.

**Omentum:** It is the fold of peritoneum which passes from the stomach to other viscera.

**Mesentery:** It is fold of peritoneum which attaches different parts of the intestine to the dorsal abdominal wall.

**Ligaments:** These are in folds of peritoneum which pass between viscera other parts of the digestive tube or connect them with the abdominal wall. These ligaments are composed of fibrous connective tissue. Some ligaments also contain smooth muscle e.g. lateral and coronary ligament of the liver and broad ligament of uterus. Ligaments are devoid of blood vessels and nerves.

The pelvic peritoneum is the continuation of that of the abdomen and it extends up to the first coccygeal vertebra. It lines the pelvic cavity and passes from sacrum to the rectum to form the meso-rectum. In males, the peritoneal fold encloses the vas deferens and the seminal vesicle gland- called the genital fold. The peritoneum that passes from the urinary bladder to the lateral walls of the pelvis is called lateral ligaments of the bladder, that passes from the ventral surface of the bladder to the floor of the pelvis, is called ventral ligament. In female, the pelvic peritoneum form, two extensive fold, the broad ligaments of the uterus, which attach the uterus to the lateral pelvic walls and lateral abdominal walls at the flank. Also, the pelvic peritoneum reflects on viscera from one organ to another forming the pelvic peritoneal pouches and folds. The pelvic pouches are sacro-rectal, recto-genital, vesico-genital and pubo-vesical pouches.





## Practical No. 3

### Demonstration of different types of joints and ligaments

An **articulation or joint** is formed by the union of two or more bones or cartilages by other tissue. Bone is the fundamental part of most joints.

**Classification of Joints:** Joints might be classified:-

#### Anatomically:

- a) According to their mode of development
- b) Nature of uniting medium
- c) The form of joint surfaces

#### Physically:

- a) On the basis of amount and kind of movement permitted or the absence of movement in them.

#### Classification of joint according to mode of development

The Joints classified developmentally as:

1. **Fibrous Joint**
2. **Cartilaginous Joints**
3. **Synovial Joints**

**Fibrous Joint:** - Here the opposing ends of bones are united by white fibrous tissue and no movement is permitted in them. e.g. Sutures and syndesmoses. The fibrous tissue connecting the bones undergoes also ossification with advancing age and this process is known as synostosis.

**Cartilaginous Joint:** - Here the bones are united by cartilage. This type of joint is again divided into two types.

**(a) Primary cartilage Joint:** - Here the uniting medium is hyaline cartilage and is the remains of the preceding continuous cartilage formation in the zones where bones are going to be formed and in the interzonal tissue and movement is absent. Synostosis usually follows in these joints.

**(b) Secondary cartilage Joint:** - Here the chondrification appears secondary in the membranous tissue between the bones (which are primarily chondrified and then ossified) and

there is a limited range of movement permitted in these joints, the opposing ends of bones connected by fibro- cartilage.

**Synovial Joint:-**Here the opposing ends of bones are free and are enclosed in a fibrous capsule lined by synovial membrane. These joints possess a wide range of movement.A synovial joint is a true joint that is characterized by the presence of joint capsule with a synovial membrane. These joints permit wide range of mobility.

Simple synovial Joints: - Formed by two articular surfaces.

Composite Joint: formed by several articular surfaces.

### **Structures involved in the formation of synovial Joint**

1. Articular surfaces
2. Articular cartilages.
3. Joint capsule
4. Ligaments
5. Articular disc or Menisci

**Classification of joints based on nature of uniting medium** and the movement permitted as

1. Synarthroses:
  - a) Sutures
  - b) Syndesmoses
  - c) Synchrondroses
  - d) Symphyses
  - e) Gomphosis
2. Amphiarthoses
3. Diarthroses

**Diarthroses** are regarded as true joints. These are characterized by the presence of a joint cavity, a synovial membrane in their joint capsule and by their mobility. They are called true joints as they permit wide range of movements. A simple joint is formed by two opposing articular surfaces and a composite joint is formed by several articular surfaces. The following structures enter into the formation of a diarthroidal joint.

**a) Articular surfaces:** - These are in most cases smooth, and very much in form. They are formed of especially dense bone, which differs histologically from ordinary compact substance. In certain cases the surface is interrupted by non-articular cavities known as synovial fossae. These may be facets, head, condyle, trochlea or concavities, glenoid cavity, cotyloid cavity etc.

**b) Articular cartilages:** - They are hyaline in type and cover the articular surfaces. They diminish concussion, reduce friction and may accentuate the curvature of the bone. Their thickness varies in different joints and the thickness is greatest in joints. These are subjected to most pressure and friction. The articular cartilages are bluish in colour.

**c) Articular or Joint Capsule:** - It consists of an outer fibrous layer (Capsular ligament) attached close to the margins or articular areas and an inner synovial membrane. The synovial layer lines the joint cavity, except where it is bounded by articular cartilages. It is a thin membrane, richly supplied with blood vessels and nerve, and secretes synovia, which lubricates the joints. Synovia resembles white of an egg in consistency but has a yellowish tinge. It contains albumen, mucin, salts and is alkaline. Articular joint cavity is a potential space enclosed by synovial and articular cartilages.

**d) Ligaments:** - These are strong bands usually composed of white fibrous tissue, which bind the bones together. In some cases they are made up of elastic tissue. The ligaments may be of various types. The peri-articular ligaments are blended with the fibrous capsule. Those ligaments which are situated on the sides of a joint are called collateral ligament. The ligaments over which the synovial membranes are reflected are called the intra-articular ligaments. The ligaments which connect directly the opposing surface of bone are called interosseous ligaments.

**e) Articular discs or Menisci:** - These are plates of fibro-cartilage or dense fibrous tissue placed between the articular cartilages, and divided the joint cavity partially or completely into two compartments. They render certain surfaces congruent, allow greater range or variety of movements and diminish concussion.

**f) Marginal Cartilage:** - It is a ring of fibro-cartilage which encircles the rim of an articular cavity. It enlarges the cavity and tends to prevent fracture of the margin.

**g) Vessels and Nerves:** - The arteries form anastomoses around the larger joints and give branches to the extremities of the bones and joint capsule. Nerve fibres are numerous in and around the synovial membrane and specialized nerve endings (Pacinian corpuscles, articular and bulb of Krause) are present.

### **Classification of diarthroidal joint**

The diarthroidal joints permits a wide range of movements to the joints. On the basis of the joint surfaces and movements which occur, the joints can be classified into-

**1. Arthrodia or gliding joint:** - In this type of joint the articular surfaces are practically flat, permitting only the gliding movement. e.g. Carpometacarpal joint.

**2. Ginglymus or Hinge joint:** - Here condyles or convexities of onw bone articulate with corresponding con cavities of another and permit only extension and flexion. E.g. Atlanto-occipital and elbow joint.

**3. Enarthroses, or ball and socket Joint:** - Here head is received into a glenoid or cotyloid cavity allowing extensive and varied movements including circumduction. e.g hip and shoulder joint.

**4. Condyloid or imperfect hinge joint:** - Where elliptical convexities articulate with concavities and except rotation all movements are permitted to varying degree.

**5. Trochoid or pivot joint:** - In this type of joint there is rotation of one bony segment around the longitudinal axis of another. e.g. atlanto –axial joint.

**EXERCISE:** Draw a well labelled diagram of a typical diarthrodial joint.



## Practical No. 4

### Demonstration of different types of muscles, tendons, synovial bursa and synovial sheath

#### MYOLOGY:

Myology deals with the study of muscles and their accessory structures such as fasciae and synovial membranes. The muscles are highly specialized organs which have the property of contraction under the influence of a stimulus and these muscles are the active organs of locomotion. The muscles are of 3 kinds viz. Voluntary (Skeletal), involuntary (smooth) and cardiac muscles. Muscles are studied keeping in view the following points.

1. Name, Shape and Position
2. Origin
3. Insertion
4. Action
5. Blood and nerve supply

The voluntary or skeletal muscles consist of bundles of multinucleated muscle cells or muscle fibres. Each muscle fibre is enclosed by a thin membrane called sarcolemma. The muscle fibres appear to have cross striations due to the presence of myofibrils (actin and myosin). Each muscle fibre is again encircled by a thin connective tissue membrane called endomysium. Now, numbers of muscle fibres unite to form a bundle or fasciculus and around each fasciculus another connective tissue sheath is found called the perimysium. Now, several fasciculi unite to form called a single muscle. Each muscle is encircled by a sheath of connective tissue called epimysium.

**Fascia:-** Fascia is the connective tissue membranes or sheath separating muscles from each other and binding them in position. Fascia is of two types – superficial fascia and deep fascia. The superficial fascia is located just beneath the skin and it contains fat. The deep fascia occurs within the groups of muscles and it sends inter muscular septa separating the muscles from each other. Deep fascia often has more than one layer and it varies in thickness.

The skeletal muscles are formed by the striated muscle fibres. These muscles fibres have different arrangements in various muscles. Hence, on the basis of arrangements of muscle fibres, the skeletal muscles can be classified as:

#### (A) Classification of skeletal muscle on the basis of arrangement of muscle fibres:

**1. Parallel muscle:** - when the muscle fibres are parallelly arranged in a muscle, then that muscle is called parallel muscle e.g. biceps brachii muscle.

**2. Pennate muscle:** - When the muscle fibres attach to the tendon of a skeletal muscle at an angle, then it is called pinnate muscle.

- a) Unipennate muscle
- b) Bipennate muscle
- c) Multipennate muscle

**3. Fusiform muscle:-**The muscle fibres of a fusiform or spindle shaped muscle converge.

**4. Cruciate muscle:-** In these muscles the fibres are arranged in superficial and deep plan crossing like “X”. e.g. masseter.

**5. Spiral muscle:-**In these muscles the fibres are arranged in a twisted manner. e.g. Brachialis muscle.

The total force exerted by a muscle contraction is the sum of forces exerted by the individual muscle fibres of that particular muscle. Now, depending upon force of action the muscles can be divided as:-

**(B) Classification of muscle on the basis of force of action:-**

**1. Spurt muscle:** - These muscles provide acceleration motion upon a joint. e.g. Brachialis muscle.

**2. Shunt Muscle:** - These muscles provide stabilizing centripetal force to a joint e.g. flexor carpi radialis muscle.

**(C) Classification of skeletal muscle according to colour:-**

**1. Red muscles:** - They are red in colour as more amounts of myoglobin pigments are present in it.

**2. White muscles:** - They are less red; possess very less amount of myoglobin pigments. These muscles are very rich in sarcoplasmic reticulum. These muscles are always placed superficially.

**Sphincters:** - These are the skeletal or voluntary muscles that surround the natural opening. e.g. Anal sphincter muscle.

**Origin of a muscle:-**The attachment of a muscle which remains more stationary during movement is called the origin of a muscle.

**Insertion of a muscle:-**The attachment of a muscle which remains much movable during movement is called insertion.

**Tendon:** The terminal narrow part of a muscle attaching to a bone is a tendon.

**Synovial membrane:** - These are thin walled sacs.



**Aponeurosis:-**The terminal broad sheet of connective tissue by the means of which the muscle is attached to the bone or other tissue is called aponeurosis.

In case of long muscles of the limbs, its *origin* is termed as head, when the muscle is fusiform then the large fleshy middle part is called *belly* of the muscle. The muscles having two heads are called biceps, those having three heads are called triceps, and those having 4 heads are called quadriceps.

The facial sheet which forms a canal in which a tendon lies, is called **annular ligament**.

The **paratendon** is the areolar connective tissue dispersed around a tendon.

### **Synovial bursa and sheath**

Bursa, a thin walled bag, contains a small amount of synovial fluid and interposed at the point of pressure between muscles, between muscle and tendon or between muscle/tendon and bone to provide friction less environment. When friction from all sides is expected, a tubular synovial bag encircles a tendon, known as synovial sheath.

### **The cutaneous muscle:-**

The cutaneous muscle in the ruminant is well developed in certain regions and is located in the superficial fascia under the skin. It is extensively attached to the skin, but seldom attached to the skeleton proper. In the head region, this muscle is called *cutaneous fasciae muscle*. This muscle is well developed in ruminants than in horse. It is located beneath the skin lying dorsally and dorso ventrally in the head region. The cutaneous muscle is present in trunk and abdomen too. The cutaneous muscle present in the region of shoulder and arm is called *cutaneous omobrachialis muscle*.



## Practical No. 5

### In situ demonstration of heart

**A. Pericardium:** - It is the fibro-serous sac which encloses the heart and covers partially blood vessels which enter and leave the heart. The pericardium consists of two layers.

**1. Fibrous layer:** It is a simple sac which is similar in form to that of the heart. It is lined internally by the parietal portion of serous layer.

**Sterno-pericardiac ligament:** The pericardium is attached to the dorsal surface of the sternum by two fibrous bands called as sterno-pericardiac ligaments.

**2. Serous layer:** It lines the medial surface of the fibrous layer and is reflected over the large vessels and the lateral surface of the heart. It is divided into two layers.

**a. Parietal layer:** It is the part of serous layer lining the fibrous layer which is closely adherent.

**b. Visceral layer:** It surrounds the heart and part of the aorta, pulmonary vessels and venae cavae. It is closely adherent to myocardium. It is also called as epicardium.

**Pericardial cavity:** It is the space between the parietal and visceral layers of serous membrane which contains a small amount of clear fluid (liquor pericardii)

**B. Heart:-** It is a hollow involuntary muscular organ lying in the chest cavity between two layers of the ventral half of the **middle mediastinal space** on left side of thoracic cavity between 3rd to 6th rib and enclosed in the pericardium.

**Shape:** It is cone shaped and slightly flattened laterally.

**Size:** The length of heart from base to apex is 22 to 25 cms.

**Weight:** Average weight is 2.5 kg (0.4 to 0.5% of the body weight)

**(B.1) External features of the heart:** It presents base, apex, borders, surfaces and grooves.

**1. Base:** The base is directed upwards and extends from the 3rd to 6th rib. The anterior part of the base is at about 10 to 12 cms from the thoracic inlet while the posterior part is at about the same distance from the tendinous center of diaphragm.

**2. Apex:** It is directed backwards, downwards and to the left. It is median in position and is near the 6th chondro-sternal articulation.

**3. Borders:** There are two borders

**a. Anterior border:** It is slightly convex, and is directed obliquely downwards and backwards. It is formed entirely by the right ventricle.

**b. Posterior border:** It is almost vertical, slightly concave and is opposite the 5th intercostal space.

**4. Surfaces:** There are two surfaces

**a. Right:** It is formed by the right ventricle and partly by the left ventricle.

**b. Left:** It is formed by the left ventricle and partly by the right ventricle.

**5. Grooves:** There are four grooves

**a. Transverse or coronary:** It runs around the base of the ventricles like a belt and indicates the division of the heart into an upper auricular and lower ventricular portion. It is not distinct at the origin of pulmonary artery.

**b. Right longitudinal:** It descends from the base of the ventricle on right surface. It begins at the transverse groove and runs towards the apex and becomes continuous with left longitudinal groove.

**c. Left longitudinal:** It also descends from base of the ventricle on left surface. It begins at the transverse groove runs and towards the apex and becomes continuous with right longitudinal groove.

**d. Intermediate:** It is shallow and found on the posterior surface. This groove turns to the left side of heart and terminates 2.5 cm above the apex.

The wall of the heart is made up of following layers:

**1. Epicardium:** It is a visceral serous layer of pericardium which is closely adherent to the wall of the heart.

**2. Myocardium:** The walls of the auricles and ventricles are made up of cardiac muscle fibres called as myocardium.

**3. Endocardium:** It lines the inside of the auricular and ventricular walls and becomes continuous with the internal tunic of vessels entering and leaving the heart.

### Vessels of Heart

**1. Arteries:** The common aorta gives off at its origin, two coronary or cardiac arteries, right and left.

**a. Right coronary artery:** It arises from the sinus of the aorta and is smaller than the left. It runs backward between the conus arteriosus and auricular appendix, reaches the auriculo-ventricular groove and proceeds backward in the groove under the lower border of the appendix.

**b. Left coronary artery:** It arises from the left posterior sinus of aorta, passes outwards to the left behind the pulmonary artery and between it and the right face of the left auricular appendix.

**2. Veins:** The veins of heart are cardiac veins. There are many small veins and a large coronary vein. The small veins carry the venous blood from the walls of right side of heart and open in right auricle by the foramina Thebesii. The large coronary vein is formed by left and right coronary veins and is joined with vena hemiazygos. The left coronary vein ascends in the left longitudinal groove almost to the level of the origin of the pulmonary artery which is in company with the descending branch of the left coronary artery, then turns backward and gains the coronary groove. Right coronary vein ascends in the right longitudinal groove and joins the trunk formed by left coronary vein and vena hemiazygos. The resulting common trunk, the great coronary vein, then terminates in the right auricle.

## **(B.2) Internal structure of Heart**

Heart comprises four chambers; the upper two chambers are atria whereas lower two are ventricles. They are named as right atrium, left atrium, right ventricle and left ventricle.

### **Right atrium**

#### **A. Openings:**

**1. Anterior vena cava:** It returns the blood from the anterior part of the body and is placed opposite the fourth rib.

**2. Posterior vena cava:** It returns the blood from the posterior part of the body and is placed opposite the fifth intercostal space.

**3. Coronary sinus:** Through this sinus, the blood is returned from the heart and is placed below the opening of posterior vena cava. It is provided with coronary valves.

**4. Vena hemiazygos:** It returns the blood from the chest and is found below the opening of the posterior vena cava and between it and the coronary sinus. (It is not found as an independent opening. It usually joins with the terminal part of the great coronary vein).

**5. Right atrio-ventricular opening:** The right auricle communicates with the right ventricle through this opening. It lies opposite the third and fourth intercostal space.

**B. Structures:**

1. **Sinus venosus:** It is a quadrangular principal cavity into which the veins open.
2. **Appendix auriculae:** It is a conical pouch which projects forwards from the sinus.
3. **Interatrial septum:** The common wall between the right and left auricle is the interatrial septum.
4. **Fossa ovalis:** It is the remnant of foramen ovale of fetus which is situated on the interatrial septum in front of the opening of posterior vena cava.
5. **Intervenous crest/tuberculum loweri:** It is a crescentic ridge which projects from the superior border of the septum downward and forward in front of the opening of posterior vena cava. It directs the flow of blood from the anterior vena cava to the right auriculo-ventricular opening.
6. **Terminal crest (Crista terminalis):** It is curved which indicates the junction of the sinus reuniens of the embryo with the atrium proper.
7. **Musculipectinati:** These are the muscular ridges in the wall of the auricular appendix.
8. **Foramen Thebesii:** These are the minute openings found in the inner face of the auricle. These return the blood from the substance of the right auricle.

**Right Ventricle**

**A. Openings:**

1. **Right auriculo-ventricular opening:** It communicates with right auricle and is guarded by a tricuspid valve.
2. **Pulmonary opening:** It is placed a little above and to the left of the right auriculo-ventricular orifice.

**B. Structures:**

1. **Tricuspid valve:** It guards the right atrio-ventricular opening and is made up of three large cusps.
2. **Chordae tendinae:** These are the thin threads given off from the musculipapillaries to the tricuspid valve.
3. **Inter-ventricular septum:** It is a common wall between the right and left ventricles.
4. **Columnaecornae/Trabeculae cornae:** These are fleshy columns or prominences, which are of three types.

(i) **Moderator band/Trabecula septomarginalis:** These bands extend from one wall of the ventricle and attached to the other wall by crossing the cavity.

(ii) **Musculipapillaris:** These are called as pillars of the heart. These are conical or nipple shaped flattened eminences. These are attached by their base to the wall of the ventricle.

(iii) **Bands and ridges:** These are the fleshy columns attached throughout their extent to the wall of the ventricle. These form an intricate network and give the wall as a sponge like character.

5. **Conus arteriosus:** The left part of the right ventricle is prolonged upward to form the conus arteriosus from which the pulmonary artery arises.

6. **Crista supraventricularis:** It is a thick ridge by which the atrio-ventricular orifice and the cavity of the conus arteriosus are separated.

### **Left atrium**

#### **A. Openings:**

1. **Openings of pulmonary veins:** There are four openings for the pulmonary veins which opens into sinus venosus.

2. **Left auriculo-ventricular opening:** The left atrium communicates with left ventricle through this opening.

#### **B. Structures:**

1. **Appendix auriculae:** It is slightly larger than that of right and its outer edge is more serrated.

2. **Sinus venosus:** The roof of this sinus has the pulmonary vein openings.

3. **Musculipectinati:** They are few but larger than those in the right one.

### **Left ventricle**

#### **A. Openings:**

1. **Left auriculo-ventricular opening:** It communicates with the left auricle and is guarded by mitral valve (bicuspid valve).

2. **Aortic opening:** It is situated at the supero-anterior part of the base of the ventricle which marks the origin of aorta. It is guarded by aortic valve which is composed of three semilunar cusps.

**B. Structures:**

**1. Bicuspid (Mitral) valve:** The left auriculo-ventricular opening is guarded by this valve which is composed of two cusps.

**2. Chordae tendinae:** They are few in number but are longer and stronger than those of the right side.

**3. Columnaecornae:** These are uneven areas by the presence of fleshy columns and prominences in the ventricles of heart.

**(i) Moderator bands:** These are variable in number; usually two bands can be seen.

**(ii) Musculipapillaris:** These are two in number corresponding to the cusps of the AV valve.

**(iii) Bands and ridges:** These are similar to those in right, but are tender and less prominent.

**4. Aortic vestibule:** The aorta begins from aortic vestibule.

**Os-cordis:** These are two small cardiac bones developed in the aortic fibrous ring. The right one is in opposite with the atrio-ventricular ring and is irregularly triangular in shape. The left one is smaller and inconstant. Its concave right border gives attachment to the left posterior cusps of the aortic valve.

**EXERCISE:** Draw a well labelled diagram of heart.





## Practical No. 6

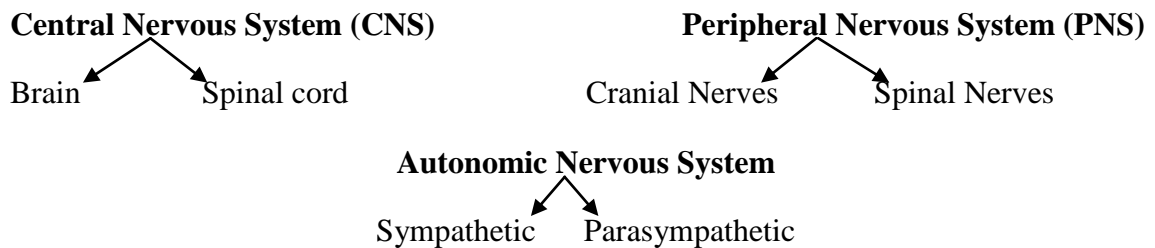
### Demonstration of meninges and spinal cord

#### Introduction to Neurology

**Neurology:** It is the description of nervous system and its functioning as to control and coordinate all the other organs and structures.

**Nervous system:** It is the communication of the body which receives the information with regard to the changes in the environment (external and internal) of the body and in response regulates appropriate function.

#### Classification of Nervous system



**A. Central Nervous System:** It includes brain and spinal cord which are enclosed by three membranous coverings for their protection known as meninges. They are duramater, arachnoid and pia mater from outward to inward.

**Brain:** Brain is the part of CNS enclosed in the cranial cavity.

**Spinal cord:** It is also the part of CNS enclosed in the vertebral canal which extends from the foramen magnum (medulla oblongata) to the middle of sacrum. The diameter of spinal cord is not uniform and enlarged at brachial plexus and lumbo-sacral plexus.

**B. Peripheral Nervous System:** It consists of cranial and spinal nerves and ganglions, and visceral peripheral nerves (autonomic nervous system).

**Cranial Nerves:** There are 12 pairs of cranial nerves connected to the base of the brain and traverse through different foramina of the skull and distributed to various organs.

**Spinal Nerves:** There is a general pattern of arrangement in the origin and distribution in all the spinal nerves in the body. They originate from the spinal cord and emerge out through the intervertebral foramen and distributed to various regions. They are generally 37 pairs in cattle, 42 in horse, 35 in dog, 39 in pig, 39 in rabbit and 36 in fowl.

Physiologically the nerves are classified according to the direction of their impulse.

**Afferent or sensory nerves:** These arise from the neurons outside the brain. They carry impulse toward the CNS arises from stimulation of sensory end organs.

**Efferent or motor nerves:** These nerves originate from the concerned nuclei in the brain. They carry impulse from the CNS to muscles and other organs. These nerve fibers may be voluntary type.

**Autonomic nervous system (ANS)/Visceral nerves:** These are involuntary efferent nerves. These nerves are divided into sympathetic or thoraco-lumbar nerves and parasympathetic or cranio-sacral nerves.

**Nerves:** These are conducting trunks composed of bundles of parallel nerve fibers.

**Nuclei:** Group of nerve cells within the central nervous system.

**Ganglia:** They are grey masses, which are the aggregations of nerve cells outside the central nervous system.

**Nerve plexus:** It is a network of nerves.

**Synapse:** It is the point of contact between terminal branches of one axon come in contact with the cell body or dendrites of other neuron. It represents contiguity without continuity.

**Neuron:** It is the structural and functional unit of the nervous system. It is composed of a cell body together with its processes, the dendrites and axons. The processes of neurons that conduct impulses away from the cell body and are termed axons or axocylinders. The dendrites are processes that conduct impulses toward the cell body.

The cell body of a neuron is variable in shape, usually containing a pale nucleus and a central nucleolus with cytoplasm characterized by stainable granules, chromophilic substance or Nissl bodies. The term neurofiber is used to include an axon and its various sheaths. A myelinated nerve fiber presents a myelin sheath, whereas a non myelinated fiber lacks of myelin sheath. The grey matter of the CNS contains cell bodies and fibers that, for the most part are non-myelinated. However, the white matter contains a large number of myelinated fibers and a few nerve cells. The sensory endings of nerve fibers are referred to as receptors.

**EXERCISE**

Classification of neuron with diagram:

a) Unipolar :

b) Bipolar:

c) Multipolar :

## To study the Meninges of Brain and Spinal cord

Meninges are the membranous coverings of brain and spinal cord. They are 3 membranes from outside to inside- Dura mater, Arachnoid and Pia mater.

### A) Cranial Meninges: (Meninges of Brain)

1) **Duramater:** It is the outer most, thickest, strong connective tissue membrane of the brain which detaches a number of folds (processes) from its inner surface:

a) **Falx cerebri:** It is a sickle shaped median partition of the dura mater situated in the longitudinal fissure between the cerebral hemispheres.

b) **Tentorium cerebelli:** It is a crescentic transverse partition or fold which occupies the transverse fissure between the cerebellum and cerebral hemispheres.

c) **Diaphragmasellae:** It is the fold of duramater which envelops the pituitary gland posteriorly and laterally and is split to enclose the cavernous sinuses. It is also called as pituitary fold.

2) **Arachnoid:** It is a delicate transparent membrane between dura and pia mater. It is composed of parietal and visceral layers. Parietal layer is firmly attached to the internal face of dura mater whereas visceral layer is loosely connected to pia mater and it bridges over sulci. There are four subarachnoid spaces or cisternae as follows:

a) **Cisterna basalis:** It extends from in front of the optic chiasma to the interpeduncular space and is continued posteriorly with cisterna pontis.

b) **Cisterna pontis:** It extends from the pituitary gland to the pons and is connected posteriorly with the spinal subarachnoid space and communicates laterally with the cisterna magna.

c) **Cisterna magna:** It communicates with the ventricles, cisterna pontis and spinal subarachnoid space. It is situated between the posterior part of the inferior face of cerebellum and the fourth ventricle.

d) **Cisterna fossae lateralis:** It is continuous with cisterna basalis.

3) **Pia mater:** It is the thin membrane closely adherent against the surface of the brain and dips into all the fissures and sulci of the brain. It is made up of connective tissue and vessels.

**Telachorioidea:** It is the fold of pia mater which forms the membranous roof to bound third ventricle superiorly.

**Chorioid plexus:** it is a vascular drainage like process of pia mater which extends from the foramen of Monro to posterior horn of the lateral ventricle.

**B) Spinal meninges (Meninges of the spinal cord):** These extend from the foramen magnum to middle of sacrum and presents following structures.

**1) Epidural space:** It is the space between the walls of spinal canal and spinal duramater which is filled with areolar and adipose tissues and plexuses of veins.

**2) Subdural space:** It is the space between the dura mater and the arachnoidea which contains the small amount of fluid that moisten the endothelial surface.

**3) Subarachnoid space:** It is the space between the visceral layer of arachnoidea and pia mater which contain cerebro-spinal fluid.

**4) Linea splendens:** It is a band like thickening of the pia mater which lies along the inferior median line of spinal cord.

**5) Ligamentum denticulatum:** It is a narrow longitudinal band formed by the series of processes given by pia mater on each side of spinal cord which runs between the superior and inferior root fibers of spinal nerves.

The differences between **cranial and spinal meninges** are as follows:

<b>Meninges</b>	<b>Cranial</b>	<b>Spinal</b>
<b>Duramater</b>	a) It is closely adherent to the cranial cavity and acts as internal periosteum of the bones  b) It detaches 3 processes from its internal face  c) It forms venous spaces	a) It is not adherent to walls of spinal canal and forms a large epidural space  b) It does not detach any process  c) It does not form any venous space
<b>Arachnoid</b>	It forms 3 subarachnoid spaces cisternae which contains the cerebro spinal fluid	Subarachnoid space is longer
<b>Piamater</b>	a) It is thin b) Extremely vascular c) Gives number of folds/processes	a) Thicker b) Less vascular c) Gives series of pointed lateral folds which pass through arachnoid and attach to duramater

### To study the Spinal cord

The spinal cord is the part of the CNS which is situated in the ventral canal. It extends from the **foramen magnum** to the **middle of sacrum** in ox. It is approximately cylindrical, but more or less flattened dorso-ventrally. The spinal nerves arise from the spinal cord and they accord in number with the number of vertebrae. The spinal cord can be divided into **-cervical, thoracic, lumbar** and **sacral** parts.

#### Number of spinal nerves in different species:

Ox	:	2(C-8, T-13, L-6, S-5, Cy-5)	=	37 pairs
Horse	:	2(C-8, T-18, L-6, S-5, Cy-5)	=	42 pairs
Dog	:	2(C-8, T-13, L-7, S-3, Cy-4-7)	=	35 or 38 pairs
Pig	:	2(C-8, T-15, L-6, S-4, Cy-6)	=	39 pairs
Rabbit	:	2(C-8, T-12, L-7, S-4, Cy-6)	=	37 pairs
Fowl	:	2(C-15, T-7, L+S-14)	=	36 pairs

**Conus medullaris:** The tapering conical portion of the spinal cord is called as conus medullaris which is situated at the level of second sacral vertebra.

**Cauda equina:** Horse tail like terminal part of the spinal cord is termed as cauda equina.

**Filum terminale:** The conus medullaris continued backward for a short distance up to fourth coccygeal vertebra. Its prolongation is called as filum terminale.

**EXERCISE:** Draw a well labelled diagram of spinal cord.





## Practical No. 7

### Demonstration of brain

**Brain:** The cephalon or the brain is that part of the central nervous system, which is contained within the cranial cavity. The average weight is about 500 gm.

**A. Dorsal surface of the brain:** In the dorsal surface of the brain the following structures are visible:

1) **Olfactory bulb:** It is flattened oval body of reddish gray colour which forms anterior extremity of olfactory tract.

2) **Frontal pole of hemisphere:** The anterior flattened extremity of each hemisphere is called as frontal pole.

3) **Cerebral pole:** The middle portion of each cerebral hemisphere is called cerebral pole.

4) **Cerebral hemispheres:** These are the largest part of the brain which occupies the cerebral compartment of the cranial cavity.

5) **Longitudinal fissure:** It is the fissure between the two cerebral hemispheres.

6) **Sylvian fissure:** It is the fissure which divides the cerebral hemisphere into an anterior and posterior lobe.

7) **Cerebral sulci and gyri:** The exterior of each hemisphere is raised into a number of irregular eminences called convolutions or gyri which are separated from each other by fissures or sulci.

8) **Cerebellar sulci and gyri:** The elevations on the surface of cerebellum are cerebellar gyri which are separated by depressions called as cerebellar sulci.

9) **Occipital pole:** The posterior flattened extremity of each hemisphere is called as occipital pole.

10) **Transverse fissure:** It is the fissure which separates the cerebral hemispheres from the cerebellum.

11) **Cerebellum:** It is lodged in the cerebellar compartment of the cranium. The body of cerebellum is divided by the longitudinal fissure into middle and two lateral lobes.

**a) Middle lobe (vermis):** It passes forwards around the anterior aspect of cerebellum to reach its under surface at about its middle.

**b) Lateral lobes:** These are separated by two deep paramedian longitudinal fissures.

**12) Medulla oblongata:** It is the posterior part of the brain stem which extends forwards as the direct continuation of spinal cord.

**B) Ventral surface of brain:** In the ventral view of the brain the following structures are visible:

**1) Olfactory bulbs:**

**2) Olfactory tracts:** These are two large bands of white matter which are continued backward and outward from postero-external angles of the optic commissure.

**3) Sulcus rhinalis:** It is the groove which passes along the inferior part of lateral surface of the hemisphere above and lateral to olfactory stria.

**4) Medial olfactory stria:** It is the root of the olfactory tract which passes backward and inward to the longitudinal fissure and then on to medial face of cerebral hemisphere.

**5) Lateral olfactory stria:** It is the root of the olfactory tract which passes backward and outward and crosses the outer part of the anterior perforated space and the sylvian fissure.

**6) Trigonomolfactorium:** It is a gray elevation situated in the angle of diversion of the medial and lateral striae.

**7) Optic nerve:**

**8) Optic chiasma:** It is the junction formed by the union of two optic tracts.

**9) Optic tracts:** These are large bands of white matter and are continued backward and outward from the postero-external angle of the optic commissure.

**10) Tuber cinerium:** It is a hollow body of gray matter situated in median line behind the optic commissure and in front of the corpus albicans.

**11) Pyriform lobe:** It is well marked prominence on the base, lateral to the optic tract and cerebral peduncle from which it is separated by deep fissure.

**12) Cerebral peduncles:** These are two large rope-like stalks which emerge from the pons close together and diverge as they pass forward to enter the cerebrum.

**13) Hypophysis cerebri (pituitary):** It is a yellowish brown discoid structure which is connected with the base of cerebrum by delicate tube called infundibulum.

**14) Inter peduncular fossa:** The area between the diverging peduncles is the interpeduncular fossa.

**15) Pons:** It is the part of brain stem which lies between the medulla and cerebral peduncle.

**16) Corpus trapezoideum:** It is the transverse band which extends across the surface immediately behind the pons.

**17) Cerebellum**

**18) Pyramid:** It is a rounded tract on either side of the ventral median fissure which is bounded laterally by a faint groove.

**19) Medulla oblongata**

**20) Choroid plexus of IVth ventricle**

**21) Oculomotor nerve**

**22) Trigeminal nerve**

**23) Glossopharyngeal nerve**

**24) Vagus nerve**

**25) Spinal accessory nerve**

**26) Hypoglossal nerve**

**C) Sagittal surface of brain:** In the sagittal surface of brain the following structures are visible:

**1) Olfactory bulbs**

**2) Callosal sulcus:** It is the fissure of the medial face of hemisphere which passes between the corpus callosum and the callosal convolution.

**3) Corpus callosum:** It is the great arched transverse commissure uniting the cerebral hemispheres and forming the roof of lateral ventricle.

**4) Lateral ventricles:** These are the irregular cavities on either side of the median line in each hemisphere. They are separated by septum lucidum.

**5) Fornix:** It is an arched structure of white longitudinal fibers placed beneath the corpus callosum. It forms the part of the floor of lateral ventricle and supports the septum lucidum.

**6) Inter-ventricular foramen (foramen of Monro):** The lateral ventricles communicate with the third ventricle through this foramen.

**7) Thalami:** These are two large ovoid masses of gray matter, placed on either side of the third ventricle and extending for a short distance behind it.

**8) Third ventricle:** It is a cavity of the diencephalon and is in the form of a narrow median space between the thalami.

**9) Epiphysis cerebri (pineal body):** It is a small ovoid or fusiform red brown mass situated in a deep central depression between the thalami and corpora quadrigemina.

**10) Corpora quadrigemina:** These are four rounded bodies arranged in pairs which lie under the posterior part of cerebral hemispheres.

**11) Cerebral peduncles (crura cerebri):** These are two large rope like stalks which emerge from the pons.

**12) Mammillary body:** It is white round elevation, a little larger than a pea which project ventrally at the anterior end of the median furrow of the inter-peduncular fossa.

**13) Pons**

**14) Medulla**

**15) Fourth ventricle:** It is the cavity of rhombencephalon or a diamond shape space situated between cerebellum above and the pons and medulla oblongata below.

**16) Cerebral aqueduct (aqueduct of Sylvius):** It is an intervening passage which connects the third ventricle with fourth.

There are three principal anatomical parts of the brain

- 1. Prosencephalon**
- 2. Mesencephalon**
- 3. Rhombencephalon**

The derivatives of these principal parts of the brain are as follows:

Primary brain vesicles	Brain subdivisions	Major derivatives	Associated ventricles
Prosencephalon (fore brain)	Telencephalon	Cerebral cortex Basal nuclei Limbic system	Lateral ventricles Anterior part of 3 <sup>rd</sup> ventricle
	Diencephalon	Thalamus, optic nerve & retina, pineal body, pituitary body	Posterior part of 3 <sup>rd</sup> ventricle
Mesencephalon (mid brain)	Mesencephalon	Tectum Corpora quadrigemina Tegmentum Cerebral peduncle	Aqueduct of Sylvius
Rhombencephalon (hind brain)	Metencephalon	Cerebellum&Pons	Rostral part of 4 <sup>th</sup> ventricle
	Myelencephalon	Medulla oblongata	Caudal part of 4 <sup>th</sup> ventricle

**EXERCISE**

Draw a well labelled diagram of brain.

## UNIT II

### Practical No. 1

#### Demonstration of scapula of ox and compare with horse, dog, pig and fowl

**Pectoral or Thoracic limb:**-It is divided into four secondary regions i.e. **shoulder, arm, forearm and the manus**. The shoulder girdle comprises of scapula, coracoid and clavicle bones out of which coracoid and clavicle are absent in animals and only scapula is present.

**Scapula:** is a flat, triangular bone, applied against lateral wall of thorax. It is directed downward and forward. It has two surfaces, three borders and three angles.

**Ox:** To be described by the student (only the salient features).

#### Horse:

- i. Spine is placed a little backward from anterior border so supraspinatus fossa comprises 1/3rd and infraspinatus 2/3rd pattern of lateral surfaces.
- ii. Subscapularis fossa is deeper and it is pointed above.
- iii. Nutrient foramen is placed at distal third of infraspinatus fossa.
- iv. Tuber scapulae and glenoid cavity are placed apart.
- v. Coracoid process is better developed.
- vi. Glenoid cavity is oval in outline and its rim shows a distinct glenoid notch on its antero medial part.
- vii. Acromion process is absent.
- viii. Neck is not distinct.

#### Dog:

- i. Shoulder region comprises of two bones - clavicle and scapula.
- ii. Clavicle is embedded in the brachiocephalicus muscle in front of the scapula. It is small, thin, irregularly triangular bony or cartilaginous plate but it does not articulate with skeleton.
- iii. Scapula is relatively longer and narrower.
- iv. Scapular spine gradually increases in height above downwards and divide the lateral surface into two equal halves.
- v. The acromion process is short, blunt and overhang the glenoid cavity.
- vi. Subscapular fossa is shallow.
- vii. Anterior border is thin and convex. Posterior border is thick & nearly straight. Vertebral border is convex.
- viii. Neck of scapula is well defined and presents posteriorly a tubercle.
- ix. Glenoid cavity is prolonged forward under tuber scapulae.
- x. Tuber scapulae are blunt & coracoid process is absent.

#### Pig:

- i. The scapular spine is triangular, wide in the middle, curves backward over infraspinatus fossa and has tuberspine in the middle.

- ii. Acromion process is rudimentary and glenoid cavity is not notched.
- iii. Tubers capulae is just above the anteromedial part of the glenoid cavity.

**\* Side identification**

- 1. Spine is lateral.
- 2. Supraspinatous fossa is anterior and infraspinatous is posterior.
- 3. Tuber scapulae is anteriorly placed.

**EXERCISE:**

- 1. Describe the salient features of scapula of ox.
- 2. Describe shoulder girdle of fowl.
- 3. Draw well labelled diagrams of lateral and medial surfaces of scapula of ox, horse, dog, pig.







## Practical No. 2

### Demonstration of humerus of ox and compare with horse, dog, pig and fowl

**Ox:** To be described by the student (only the salient features).

**Horse:**

- i. Musculo spiral groove is deeper and curved.
- ii. Nutrient foramen is placed on distal third of medial surface.
- iii. Deltoid tuberosity is better developed.
- iv. Head is smaller and neck is distinct.
- v. Bicipital groove is sub divided by an intermitted ridge.
- vi. The summit of the lateral tuberosity is not high.
- vii. Ridge on distal articular surface is less prominent.

**Dog:**

- i. Relatively long and slender, is less spirally twisted.
- ii. Deltoid tuberosity is ridge like.
- iii. Teres tubercle is a raised rough area.
- iv. Nutrient foramen is placed on posterior surface.
- v. Head is rounded and strongly convex.
- vi. Lateral tuberosity is single while bicipital groove is undivided.
- vii. The coronoid and olecranon fossa are usually communicated by a large foramen (supra trochlear foramen)

**Pig:**

- i. Shaft is compressed from side to side.
- ii. Teres tubercle is absent.
- iii. Musculospiral groove is shallow.
- iv. Deltoid tuberosity is small.
- v. Head is more strongly curved and neck is better marked.
- vi. Lateral tuberosity is large and divided into two high prominences by a wide deep groove. Third eminence is also present.
- vii. Olecranon fossa is very deep & separated from coronoid fossa by a thin bony plate this is sometimes perforated.

**\* Side Identification**

- i. Head is posterior.
- ii. Deltoid tuberosity and crest is lateral

**EXERCISE:**

1. Describe the salient features of humerus of ox.
2. Describe humerus of fowl
3. Draw a well labelled diagrams of Humerus of ox, horse, dog, pig, and fowl.







### Practical No. 3

#### Demonstration of radius and ulna of ox and compare with horse, dog, pig and fowl

**Radius and Ulna of ox:** To be described by the student (only the salient features).

#### **Radius and Ulna of Horse:**

- i. Radius is larger and longer than ulna
- ii. Radial tuberosity is larger.
- iii. Grooves on distal part of anterior surface are better marked.
- iv. Distal articular surfaces of shaft are straight
- v. Ulna is an aborted bone and reaches only up to the mid of radius
- vi. Styloid process is absent
- vii. Single interosseous surface is present.

#### **Radius and Ulna of Dog:**

- i. Radius is attached to ulna only at two extremities thereby permit certain degree of movement.
- ii. The shafts of two bones are separated by a narrow interosseous space.
- iii. Proximal extremities of radius are small and have distinct neck.
- iv. Posterior surface has convex marginal articular area for circumferentiaarticularis of ulna.
- v. Radial tuberosity is small.
- vi. Distal extremity is much wider, its medial border projects downward to form styloid process of radius.
- vii. Ulna is an independent & well developed bone which crosses posterior surface of radius medio-laterally.
- viii. Shaft is three sided at proximal third while smaller and rounded below.
- ix. Anterior surface is rough & nutrient foramen is proximally placed.
- x. Proximal extremity is short, concave, smooth medially and convex, rough laterally.
- xi. Summit is grooved & has three prominences, posterior one is large & rounded.
- xii. Semilunar notch is narrow, transversely placed, concave and articular.
- xiii. Distal extremity is prolonged into a blunt pointed styloid process has concave facet for ulnar carpal below & convex facet for radius antero medially.

#### **Fig:**

- i. Radius of pig is short, narrow but thick. Posterior surface is in apposition with ulna & marked by a vascular furrow which runs distally.
- ii. Radial tuberosity is represented by a rough area.
- iii. Distal end is relatively large, has only two concavo-convex facets for radial and intermediate carpal bones.
- iv. Ulna is massive, longer and heavier than radius.

- v. Its shaft is curved; dorsal, dorsal surface is convex & rough attached to radius by interosseous ligament.
- vi. Medial surface of ulna is concave, smooth and lateral surface is slightly concave.
- vii. Proximal extremity is larger bent medially.
- viii. Distal extremity is small articulates with ulnar and accessory carpal bones.
- ix. Medullary cavity is considerably present.

**\* Side identification:**

- i. Radius is present medially and ulna laterally
- ii. Olecranon process is inclined laterally
- iii. Styloid process – is a bony pillar like process present laterally

**EXERCISE:**

- 1. Describe the salient features of radius and ulna of ox.
- 2. Describe salient features of radius and ulna of fowl.
- 3. Draw well labelled diagrams of radius and ulna of ox, horse, dog, pig, and fowl.







### Practical No. 4

#### Demonstration of carpals and metacarpals of ox and compare with horse, dog, pig and fowl

The skeleton of the manus consists of: Carpals, Metacarpus and Digits. In the domestic animals the basis corpus number is 8. There are 4 bones proximally and four ventrally as follows:

<b>Medial Side</b>	Radial	Intermediate	Ulnar	Accessory	<b>Lateral Side</b>
	1 <sup>st</sup>	2 <sup>nd</sup>	3 <sup>rd</sup>	4 <sup>th</sup>	

**Ox:** To be described by the student (only the salient features).

**Horse:**

<b>Proximal Row</b>	Radial	Intermediate	Ulnar	Accessory*	* Accessory articulates with Radius and Ulnar carpal
<b>Distal Row</b>	1 <sup>st</sup> (present occasionally)	2 <sup>nd</sup>	3 <sup>rd</sup>	4 <sup>th</sup>	

**Dog:**

<b>Proximal Row</b>	(Radial +Intermediate)		Ulnar	Accessory*	* Accessory articulates with Ulna and Ulnar carpal
<b>Distal Row</b>	1 <sup>st</sup>	2 <sup>nd</sup>	3 <sup>rd</sup>	4 <sup>th</sup>	

**Pig:-**

<b>Proximal Row</b>	Radial	Intermediate	Ulnar	Accessory*	* Accessory articulates only with Ulnar carpal.
<b>Distal Row</b>	1 <sup>st</sup>	2 <sup>nd</sup>	3 <sup>rd</sup>	4 <sup>th</sup>	

#### Metacarpus and Digits:-

The digital region is the terminal segment of **the manus** .The typical mammalian manus (e.g. Dog) comprises of five digits, each of which bears three phalanges.

**Ox: -3rd and 4th Metacarpal bones** are well developed and fused represent large metacarpal large metacarpal it is a long bone having shaft and two extremities. Anterior surface of shaft is smooth, rounded and transversed vertically by anterior vascular groove having two foramina i.e. proximal and distal. They communicate with similar foramina present on posterior surface. Posterior surface is flat having shallow posterior vertical groove .It is in contact with suspensory ligament 5th is vestigial and represent small metacarpal bone. It is rod like placed on proximal part of lateral border of large metacarpal bone .Proximal end is rounded and rough while distal end tapers to a point.

**Horse: -3rd metacarpal** is functional and represent large metacarpal. The anterior and posterior grooves are absent. Proximal extremity has two facets and posterior surfaces for articulation of small metacarpal bones. Distal extremity is undivided. 2nd and 4th are vestigial and are termed as splint bones or small metacarpals (medial and lateral). Medial one is slightly longer. The distal extremity of medial splint bone is nodular and termed the button of splint bone and can be felt in living animal.

**Dog: - All metacarpal** (1st, 2nd, 3rd, 4th, and 5th) are well developed and bears digits.

**Pig: - 2nd, 3rd, 4th and 5th metacarpals** are developed.

**EXERCISE** Draw a well labelled diagrams of carpals and metacarpals of ox, horse, dog, pig.



## Practical No. 5

### Demonstration of phalanges and sesamoids of ox and compare with horse, dog, pig and fowl

**Digits:** - There are two digits in ox in each limb and each digit carries three phalanges and three sesamoid bones.

The **first phalanx** is the longest among the three. It consists of a shaft and two extremities.

**Shaft:** - is three sided and presents three surfaces. Dorsal/anterior, volar/posterior and Inter digital.

**Proximal extremity:** - consists of two glenoid cavities separated by a sagittal groove of which the lateral/ abaxial one is larger. Behind there are two facets for articulation with sesamoid bones.

**Distal extremity:** - consists of a trochlear articulation

The **second phalanx** is also similar in structure as the first phalanx except its size is about 2/3rd length of the first phalanx.

**Surfaces:** - Proximal/ Articular, Dorsal / Anterior, posterior / volar and interdigital. On the posterior aspect of the proximal / articular surfaces, there is a facet for articulation with distal sesamoid bones. The coronary border bears above eminence above the proximal angle known as extensor process

**Horse:** -Only one digit (third) is present and it has phalanges and three sesamoid bones.

The **first phalanx** is flatted anteroposteriorly .It is larger and wider .Posterior surfaces have two ridges which cover inferiorly in shape of letter “V”. As there is one digit, so there is no interdigital surface. The **second phalanx** is just half in the length of the phalanx and is four sided bone. The **third phalanx** is very wide and longer and for description it presents:-

Three surfaces: - Articular surface, Dorsal/ wall surface and volar / solar surface.

**Dog:** - **All metacarpal** (1st, 2nd, 3rd, 4th, and 5th) are well developed and bears digits. Digit 1 possesses only two phalanges. So it does not come in contact with ground while walking. Rest all digits have 3 phalanges each. 3rd and 4th digits are the longest. 3rd phalange resembles with claw or hooks like and encircled by a collar of bone.

**Pig:** - **2nd, 3rd, 4th and 5th metacarpals** are developed. All metacarpals bear digits. 3rd and 4th are functional. Chief digits (3rd and 4th) comprizes of three phalanges and three sessamoids. Phalanges of 2nd and 4th are small and generally do not reach the ground.

### **Sessamoids:**

**Ox:** - To be described by the student (only the salient features).

**Horse:** There are two proximal Sessamoids in each limb and one distal sesamoid in each limb (total 12). Proximal have three sides, pyramidal in shape and **distal one is shuttle shaped**.

**Dog:** - Proximal Sessamoids are anterior and posterior. Anterior five are in the form of nodules in capsular ligaments of joints for each limb .Two posterior Sessamoids are present behind each metacarpo phalangeal joint from 2nd to 5th and one in first digit (total 52). **Distal sessamoids are absent in dog**

**Pig:** -There are two proximal and one distal sesamoid bone in each digit (total 48)

#### **\* Side identification:-**

1. Large metacarpal of horse and ox: - Metacarpal tuberosity is medial.
2. Medial facet in proximal extremity is larger than lateral one.
3. In distal extremity medial condyle is lower in position.

**EXERCISE:** Draw a well labelled diagram of phalanges and sesamoid bones of different domestic animals.



## Practical No. 6

### Dissection of forelimb: Study of muscles of forelimb

#### Muscles of the shoulder girdle / thoracic girdle

The muscles of the shoulder girdle are located in dorsal and ventral groups when attach the thoracic limb to the head, neck and trunk. Since, there is no as such any articulation of the thoracic limb to that of the neck, head and throax, and then muscles (8 Numbers) attach the thoracic limbs to head, neck and trunk therefore this group of 8 muscles (muscles of thoracic girdle ) is called muscles of synsarcosis. They are as follows:

**1. M. Trapezius:-**It is a wide, undivided, flat and triangular muscle. This originates from the atlas to the spines of 12th or 13th thoracic vertebra. It has got two parts – cervical and thoracic, although there is no clear cut- demarcation.

*a) Cervical part:* - It is thin, triangular sheet in the cervical region.

**Origin:** A median fibrous raphe common to the right and left- muscle extending from the 1st or 2nd thoracic vertebra to the level of axis.

**Insertion:** The scapular spine and deep fascia overlying the infraspinatus muscle.

**Action:** To pull the scapula dorsad and craniad and to incline the head and neck laterally.

**Blood Supply:** Vertebral, deep cervical, dorsal scapular and dorsal intercostal arteries.

**Nerve Supply:** Dorsal branch of spinal accessory nerve.

*b) Throacic part:* - It is also triangular in appearance. It is less extensive, but considerably thicker than the cervical part.

**Origin:** The spines of all thoracic vertebrae and the thoraco lumbar fascia.

**Insertion:** The scapular spine by means of a flat aponeurotic sheet.

**Action:** Draw the scapula caudad&dorsad. (both parts act together to draw the scapula dorsal)

**Blood & Nerve Supply:** - Same as cervical part.

**2. M. Omotransversarius:** - It is located on the lateral surface of the neck, extending from the wing of atlas to the shoulder. It follows the deep face of the brachiocephalicus muscle .The caudal part of the muscle lies between the brachiocephalicus and cervical part of the trapezius muscles.

**Origin:** Wing of atlas by an aponeurotic band.

**Insertion:** The fascia of the shoulder, and thus indirectly to the scapular spine.

**Blood Supply:** Vertebral and superficial cervical arteries.

**Nerve Supply:** Cervical spinal nerves and accessory spinal nerve.

**Structure:** This muscle is quite indistinct from brachiocephalicsthroughout most of its course. The caudal part of the muscle is subcutaneous.

**3. M. Latissimus dorsi:** - It is a flat, relatively thin and triangular muscle and covers most of the lateral surface of the thorax. It has a broad tendon of origin which blends with the Thoraco-



lumbar fascia as well as fascia over the external inter-costal muscle. Together with the teres major, the Latissimus dorsi attaches to the teres tuberosity of the humerus.

**Origin:** The superficial layer of Thoraco-lumbar fascia from the 4th thoracic to the last lumbar spines as well as from the lateral surfaces of the 9th to 12th ribs.

**Insertion:** Teres tuberosity.

**Action:** It draws the trunk cranially when the limb is advanced.

**Blood Supply:** Thoraco dorsal artery and dorsal intercostal artery.

**Nerve Supply:** Thoraco dorsal nerve.

**1. M. Brachiocephalicus:** - It is a thin muscle which extends along the side of the neck from the head to the arm. It lies directly beneath the skin. It is completely divisible into two portions – Cleido-occipitalis and cleido-mastoideus, the former being located dorsally and the latter ventrally.

**Origin:** The cleido-occipitalis arises from the occipital bone and the ligamentum nuchae. The cleidomastoideus is smaller and arises from the mastoid process of the petrous part of the temporal bone.

**Insertion:** Crest of humerus distal to the deltoid tuberosity, and the fascia of the arm & forearm.

**Blood Supply:** Deep cervical, vertebral and superficial cervical arteries.

**Nerve Supply:** Ventral branches of the cervical spinal nerves, spinal accessory and axillary nerves.

**Structure:** - The muscle is almost entirely fleshy. In the neck region, its ventral border forms the dorsal boundary of the jugular furrow.

**2.M. Rhomboideus:** - It arises on the ligamentum nuchae from the 2nd cervical (axis) to the 5th thoracic vertebrae, It is attached to the deep surface (medial surface) of the scapular cartilage and extends cranially and dorsal to the level of the axis under the cervical part of the trapezius. It has got two parts viz. cervical and thoracic parts. Although no clear cut- demarcation is noticed.

**Origin:**-The cervical part originates from the 2nd thoracic to 2nd cervical vertebrae. The thoracic part originates from the 2nd to the 5th thoracic spines.

**Insertion:**-Cranio-medial surface of the scapular cartilage for the cervical part and caudomedial surface of the scapular spine for the thoracic part.

**Action:** - The cervical part aids in drawing the scapula dorsally and cranially when the neck is fixed. The thoracic part draws the scapula dorsally and medially and aids in supporting the limb when it is in motion.

**Blood Supply:** - Branches of deep cervical and dorsal scapular arteries.

**Nerve Supply:** - Branches of the cervical and thoracic spinal nerves.

**6. M. Superficial Pectoral:** - This muscle is less divided in the ruminant than in the horse; and its two parts viz. Cranial superficial pectoral and caudal superficial pectoral are not very distinct.

This muscle extends from the ventral and cranial parts of the sternum to the medial surface of the arm and forearm.

**a) Cranial superficial pectoral:**-It lies superficial to the cranial border of the caudal superficial pectoral muscle.

**Origin:** - It is a thin muscle which extends from the 1st sternebra to the humerus..and is quite intimately attached to the caudal superficial pectoral muscle by which it can be distinguished by its red colour.( deeper dark colour).

**Insertion:** - On the crest of humerus.

**Action:** - Adduction of the limb.

**Structure:** - In the ox, it presents fibre bundles which are coarse and thick. The fibres of the brachial portion appear quite horizontal and are directed caudal and lateral to the distal portion of the humerus.

**Blood Supply:** - External thoracic and transverse cubital arteries.

**Nerve Supply:** - Cranial pectoral nerves.

**b) Caudal superficial pectoral:** - It is a thin, pale coloured muscle which extends caudally to the 6th sternebra in the ox. This part of the superficial pectoral muscle is poorly developed in both ox and small ruminants.

**Origin:** - From the 2nd to the 4th or 6th sternal segments and from the corresponding muscle of the opposite side.

**Insertion:** - Into the fascia of the medial aspect of the forearm and continuous along its caudal edge with the cutaneous trunci muscle.

**Blood Supply:** - External thoracic and collateral ulnar arteries.

**Nerve Supply:** - Cranial pectoral nerve.

**7. M. Deep pectoral:** - It is a large muscle whose fibres are usually directed longitudinally along the ventral thoracic wall. It is covered in most part by the superficial pectoral muscle.

**Origin:** - The ventral surface of the sternum and the abdominal tunic.

**Insertion:** - Medial tuberosity of the humerus.

**Action:** - To adduct and retract the limb.

**Blood Supply:** - External thoracic artery.

**Nerve Supply:** - Cranial pectoral nerve.

**8. M. Serratus ventralis:**-It is a large fan shaped muscle located on the lateral surface of the neck and thorax. It consists of 2 parts. viz. a cervical part called serratus ventralis cervicis and thoracic part- called serratus ventralis thoracic. It receives its name from the serrated ventral edge of its thoracic part.

**a) M. Serratus ventralis cervicis** - It is well developed in ruminants. It covers the caudal half of the lateral surface of the neck.

**Origin:** - The transverse process of the 3rd to 7th cervical vertebrae.

**Insertion:** - In the triangular area on the dorso- cranial angle of the medial surface of the scapula.

**b) *M. Serratus ventralis thoracis:*** - It covers the cranial half of the lateral thoracic wall. The thoracic part is covered by a strong aponeurosis.

**Origin:** - Lateral surface of the thorax on the first 8th to 9th ribs.

**Insertion:** - On the caudal angle of scapula on its medial surface and on its muscular lines.

**Action:** - (Serratus ventralis as a whole) suspend the trunk between the two scapulae. It also helps in inspiration.

**Blood Supply:** - Costocervical trunk and supreme intercostal arteries.

**Nerve Supply:** - 5th to 8th cervical spinal nerves and the long thoracic nerve.

**EXERCISE:** Draw a well labelled diagram showing muscles of shoulder girdle.

## **Muscles of the shoulder and arm**

There are 7 numbers of muscles are there which act upon the shoulder joint .They can be divided into flexors and extensors of the shoulder joint.The flexor muscle can be again grouped into lateral flexor division and medial flexor division.

The muscles of lateral flexor division are:-

1. **M. Deltoideus:** - It is clearly divided into acromial and scapular parts.

**Origin:** - The acromian process of the scapula, scapular spine &caudal border of scapula.

**Insertion:** - Both the parts join to attach to the deltoid tuberosity of the humerus.

**Structure:** - This muscle is divided into acromial and scapular parts by a tendinous intersection. The acromial part is spindle shaped; whereas the scapular part is flattened.

**Blood Supply:** - Circumflex scapular, subscapular and caudal circumflex humeral arteries.

**Nerve Supply:** - Axillary nerve.

**Action:** - To flex the shoulder joint.

2. **M. Teres minor:** - It is a small muscle which lies caudolateral to the shoulder joint under cover of the deltoideus and caudal to the infraspinatus.

**Origin:** - By means of tendinous fibres from the distal half of the caudal border of **scapula**.

**Insertion:** - Greater tuberosity of humerus proximal to the deltoid tuberosity.

**Blood Supply:** - caudal circumflex humeral artery.

**Nerve supply:-** Axillary nerve.

3. **M. Infraspinatus:** - It is a powerful, heavily tendinous muscle, which fills the entire infraspinatus fossa.

**Origin:** - The infraspinous fossa, spine of scapula and scapular cartilage.

**Insertion:** - On the medial surface and the caudal part of the greater tubercle (lateral tuberosity) of humerus.

**Action:** - To serve as a lateral collateral ligament of the shoulder .It also serves to abduct the arm.

**Blood Supply:** - Circumflex scapular artery and caudal circumflex humeral artery.

**Nerve Supply:** - Supra scapular nerve.

**The muscles of the medial flexor divisions are:-**

4. **M. Subscapularis:-** It consists of three parts with a common tendon of insertion.

**Origin:** - The scapular cartilage and the entire subscapular fossa.

**Insertion:-** The lesser tubercle (medial tuberosity) of the humerus.

**Action:** - Major function is adduction.

**Blood Supply:** - Subscapular, circumflex scapular and suprascapular arteries.

**Nerve Supply:** - Subscapular and axillary nerves.

5. **M. Teres Major:-** It is somewhat flattened muscle and extends from the caudal border of the scapula to the teres tuberosity of the humerus, lying chiefly on the medial surface of the triceps brachii.

**Origin:** - The caudal angle and caudal border of scapula as well as the subscapularis.

**Insertion:** - Teres major tuberosity with the tendon of Latissimus dorsi muscle.

**Action:** - To flex the shoulder joint.

**Structure:** - It is a spindle shaped muscle, which is widest at the level of the shoulder joint. Its aponeurosis blends with that of the tensor fasciae antebrachii caudal to the tendon of insertion.

**Blood Supply:** - Subscapular, thoraco dorsal and circumflex scapular arteries.

**Nerve Supply:** - Axillary nerve.

6. **M. Coracobrachialis:** - It is a flat muscle lying on the medial surface of the shoulder joint and the arm and it obliquely crosses the shoulder joint to terminate on the medial side of the humerus.

**Origin:** - The coracoid process of the scapula.

**Insertion:** - Teres major tuberosity of the humerus.

**Action:** - To adduct the arm and flex the shoulder.

**Structure:** - The muscle emerges between the subscapularis and the medial branch of the supraspinatus muscle. As it passes over the terminal part of the subscapularis, it is provided with a synovial bursa.

**Blood Supply:** - Cranial circumflex humeral, subscapular and transverse cubital arteries.

**Nerve Supply:** - Musculo cutaneous nerve.

#### **Extensors of the shoulder joint:-**

There is only one extensor muscle which act as shoulder joint called *M. Supraspinatus*.

7. **M. Supraspinatus:** - It is powerful in ox. It is lodged in the supraspinous fossa.

**Origin:** - The supraspinous fossa, the scapular spine and ventral part of scapular cartilage.

**Insertion:** - Lateral and medial tuberosities of humerus.

**Action:** - To extend the shoulder joint.

#### **Muscles of the arm**

This group consists of muscles which are grouped around the humerus. Some arise from the scapula and others from the humerus. All these muscles are inserted to the forearm.

#### **These muscles can be divided into:-**

A) **Flexors of the elbow joint:** - They flex the elbow joint.

B) **Extensors of the elbow joint:** - They extend the elbow joint.

## A. Flexors of the elbow joint:

1. **M. Biceps brachii**:- It is a small muscle which lies on the cranial surface of the humerus...

**Origin:** - The supraglenoid tubercle of the scapula.

**Insertion:**-The radial tuberosity and cranial surface of radius, just cranial to the insertion of brachialis muscle.

**Blood Supply:** - Bicipital, external thoracic and brachial arteries.

**Nerve Supply:** - Musculocutaneous nerve.

2. **M.Brachialis**:-. It occupies the musculo-spiral groove on the lateral side of the humerus. This muscle is thick and fleshy. It crosses the biceps brachii obliquely, passing between the biceps brachii and the extensor carpi radialis to terminate on the medial side of the forearm.

**Origin:** - The Proximal third of the caudal surface of the humerus.

**Insertion:** - Just distal to the radial tuberosity and on the medial border of the radius.

**Blood Supply:** - Caudal circumflex humeral and transverse cubital arteries.

**Nerve Supply:** - Musculocutaneous nerve.

3. **M. Pronator teres:** - It is represented by a weak, narrow band of muscle situated on the medial surface of the elbow, extending to the medial border of the radius.

**Origin:** - The medial epicondyle of the humerus.

**Insertion:** - The medial border of the radius.

**Relation:** - It is located cranial to the flexor carpi radialis.

**Blood Supply:** - Branches of median and brachial arteries.

**Nerve Supply:** - Median nerve.

## B. Extensors of the elbow joint:

The extensors of the elbow are better developed than the flexors the domestic animals. They serve to support the weight of the cranial part of the body .They are as follows:

4. **M. Tensor fasciaeantebrachii:** It is a slender, thin and long muscle that lies along the caudal border and somewhat medial to the long head of the triceps brachii. It extends from the caudal angle of scapula to the medial side of the olecranon process.

**Origin:** - Caudal border of scapula and from the Latissimus dorsi muscle distally.

**Insertion:**-It terminates by means of a narrow, flat tendon on the medial surface of the olecranon and the antebrachial fascia.

**Blood Supply:** - Thoracodorsal artery.

**Nerve Supply:** - Radial nerve.

5. **M. Triceps brachii:** It is a large muscle that fills the angle between the caudal border of the scapula and humerus and is the major extensor of the elbow joint.

The triceps brachii muscle has got 3 heads, namely longhead, medial head and lateral head.

- a) **Long head of triceps brachii:** - It is the largest of the three heads. It occupies the flexor angle of the shoulder joint.  
**Origin:** - Caudal border of the scapula.  
**Insertion:** - Lateral and caudal parts of the summit of olecranon.  
**Action:** - The long head has a dual function. It extends the elbow joint and flexes the shoulder joint.
- b) **Lateral head of triceps brachii:** - It is broad and flat and is separated from the long head by the caudal circumflex humeral artery and axillary nerve. It is quadrilateral in shape and lies on the lateral surface of the arm.  
**Origin:** - The curve line extending from the deltoid tuberosity to the neck of the humerus.  
**Insertion:** - Tendon of long head and lateral aspect of the olecranon.  
**Action:** - To extend the elbow joint.
- c) **Medial head of triceps brachii:** - It is covered to some extent by the long head and is situated on the medial surface of humerus.  
**Origin:** - Medial surface of the body of the humerus, caudal and distal to the teres tuberosity.  
**Insertion:** - Medial and cranial portion of the olecranon.  
**Action:** - To extend the elbow joint.  
**Blood Supply:** - (Triceps brachii): Caudal circumflex humeral, circumflex scapular, thoraco dorsal, brachial and deep brachial arteries.  
**Nerve Supply:** - Radial nerve.
6. **M. Anconeus:** - It is a small muscle which occupies the olecranon fossa.  
**Origin:** - The caudal surface of the distal third of the body of humerus and the bony edge of the olecranon fossa.  
**Insertion:** - The cranial border and lateral surface of the olecranon.  
**Action:** - To extend the elbow joint.  
**Blood Supply:** - Collateral ulnar artery.  
**Nerve Supply:** - Radial nerve.

### Muscles of the forearm and manus

These muscles can be divided into:- **A. Extensor group. And B. Flexor group.**

**A. Extensor group.** (Located cranio lateral to the forearm)

1. **M. Extensor carpi radialis:** - It is the largest muscle of the extensor group. Throughout most of its course, it lies upon the cranial surface of the radius.  
**Origin:** - Lateral epicondyle of humerus and radial fossa.  
**Insertion:** - By means of a broad, flat tendon onto the metacarpal tuberosity.  
**Action:** - To extend and fix the carpal joint and flex the elbow joint.  
**Blood Supply:** - Transverse cubital and cranial interosseous arteries.  
**Nerve Supply:** - Radial nerve.

2. **M. Medial digital extensor:-** (Extensor muscle to the III digit) This muscle is situated lateral to the proceeding.
  - Origin:** - Lateral epicondyle of humerus and radial fossa.
  - Insertion:**--Second and third phalanges of the medial digit (III)
  - Action:** - To extend the carpal and digital joints (medial digit).
  - Blood Supply:** - Transverse cubital and cranial interosseous arteries.
  - Nerve Supply:** - Radial nerve.
  
3. **M. Common digital extensor:** - It is a long slender muscle situated lateral to the preceding. It has two heads of origin.
  - Origin:** - Lateral epicondyle of the humerus.
  - Insertion:** - Extensor process of the 3<sup>rd</sup> phalanges of both III<sup>rd</sup> and IV<sup>th</sup> digits (Its tendon divided into 2 parts to enter III and IV digits).
  - Action:** - To extend the carpal joint and to approximate the digits.
  - Blood Supply:** - Transverse cubital and cranial interosseous arteries.
  - Nerve Supply:** - Radial nerve.
  
4. **M. Lateral digital extensor:** - It is the caudal most muscle functioning as an extensor. (The ulnar is lateralis muscle which lies caudally, act only as flexor not, as extensor) This muscle has an extensive origin.
  - Origin:** - Lateral epicondyle of humerus, lateral aspect of the radial head and caudo lateral surface of the ulna.
  - Insertion:** - Proximal extremity of the middle phalanx of the IV<sup>th</sup> digit. An abaxial tendon also inserted to the parietal surface of the distal phalanx of the IV<sup>th</sup> digit.
  - Action:** - To extend the lateral digit (IV<sup>th</sup> digit) and the carpal joint & to flex the elbow joint.
  - Blood Supply:**--Transverse cubital and cranial interosseous arteries.
  - Nerve Supply:**-- Radial nerve.
  
5. **M. Extensor carpi obliquus:-** It is a thin and flat muscle that lies deeply to the other members of the extensor group. It courses obliquely across the dorsal surface of the carpus. The tendon of insertion of this muscle runs obliquely over the tendon of extensor carpi radialis muscle.
  - Origin:** - Lateral surface of the distal half of the radius & cranio-lateral edge of the ulna.
  - Insertion:** - The mediopalmar surface of proximal extremity of the large metacarpal bone.
  - Blood Supply:** - Cranial interosseous artery.
  - Nerve Supply:** - Radial nerve.



## **B. Flexor group:-**

### **(Superficial layer)**

- 1. M. Pronator teres:-** It is a very small muscle situated along the medial face of the elbow joint (closely blended with the medial lateral ligament).

**Origin:** - Medial epicondyle of the humerus.

**Insertion:** - Upper part of the medial border of the radius.

**Action:** - Inappreciable, as it is vestigial.

**Blood Supply:-** Median artery.

**Nerve Supply:** - Median nerve.

- 2. M. Flexor carpi radialis:** - It lies along the caudomedial surface of the forearm. The origin is lateral while the insertion is caudal.

**Origin:** - Medial epicondyle of humerus caudal to the origin of the pronator teres muscle.

**Insertion:-**Mediopalmar surface of the proximal end or base of the large metacarpal bone.

**Action:** - To flex the carpal joint and extend the elbow.

**Relationship:** - Superficially skin and fascia. Deeply elbow joint, humerus, head of deep digital flexor, radius and carpus. Cranially pronator teres. Caudally flexor carpi ulnaris.

**Blood Supply:** - collateral ulnar and brachial arteries.

**Nerve Supply:** - Median nerve.

- 3. M. Flexor carpi ulnaris:** - It is wide, thin flat muscle which partially cover the remainder of the flexor group. It lies superficially on the caudomedial aspect of the forearm.

**Origin:** - The ulnar head arises from the caudal and medial surfaces of the olecranon .The humeral head arise from the medial epicondyle of humerus just caudal to the origin of flexor carpi radialis muscle.

**Insertion:-**In common with the caudal tendon of insertion of the ulnaris lateral muscle into the proximal border and lateral surface of the accessory carpal bone.

**Action:** - To flex the carpal joint and extend the elbow joint.

**Structure:** - This flat muscle arises by two widespread tendons. The ulnar part from the olecranon and the humeral part from the medial epicondyle of humerus– a “V” shaped origin.

- 4. M. Ulnarislateralis:** - It is a large, thick, strap like muscle situated behind the lateral digital extensor. Although morphologically it belongs to the extensor group, but actually functionally it is a flexor muscle.

**Origin:** - The lateral epicondyle of the humerus.

**Insertion:-**Lateral surface and proximal border of the accessory carpal bone and into the lateral surface of the proximal end or base of the large metacarpal bone.

**Action:** - To flex the carpal joint and extend the elbow joint.

**Blood Supply:** - Common interosseous, cranial interosseous and brachial artery.

**Nerve Supply:** - Radial nerve.

**(Deep layer)**

5. **M. Superficial digital flexor:** - This muscle remains under cover of the flexor carpi Ulnaris. It divides into two bellies-superficial and deep, terminating on tendons at the distal part of the forearm. The superficial tendon passes over the flexor retinaculum, perforates the metacarpal fascia, and joins the deep tendon about the middle of the metacarpus. The deep belly is connected with the deep digital flexor muscle by a strong fibrous band.

**Origin:-**The medial epicondyle of the humerus.

**Insertion:-**The proximal extremity of the palmar surface of the middle phalanx of the 3<sup>rd</sup> and 4<sup>th</sup> digits.

**Action:-** To flex the carpus and digit and extend the elbow.

**Blood Supply:-**Collateral ulnar and common interosseous arteries.

**Nerve Supply:-**Ulnar nerve.

6. **M. Deep digital flexor:-** This is the largest of the flexor muscles and remains partly covered by the superficial digital flexor muscle. This muscle has got 3 heads –the humeral head, radial head and ulnar head. The humeral head is the largest, the radial head is the deepest and the ulnar head lies most laterally.

**a) The radial head:**

**Origin:-** The caudal surface of the proximal extremity or head of radius, also the proximal interosseous space.

**Structure:-**The radial head is thin and small. It is the deepest of the three heads. It is flat and somewhat triangular with a narrow rounded tendon of insertion.

**Relations:-** superficially, humeral head of deep digital flexor muscle; deeply, radius.

- b) The humeral head:-** The large humeral head may be further divided into a large and small heads. They are fleshy and nearly equal in size.

**Origin:** - Medial epicondyle of the humerus.

**Relations:-** Superficially, ulnar is lateralis and the ulnar head of deep digital flexor muscle, caudo medially, flexor carpi ulnaris muscle.

**c) The Ulnar head:-**

**Origin:-**Medial, caudal and lateral surfaces of the proximal end of the ulna.

**Structure:-**It is fleshy, triangular and short. It has an extensive origin.

**Relations:-** Superficially, ulnaris lateralis, deeply long and medial heads of triceps brachii and humeral head of deep digital flexor muscle.

**Insertion :-** (Deep digital flexor). The flexor tubercle of the distal phalanx of the third and fourth digits.

**Blood Supply:** - Collateral ulnar, brachial and common interosseous arteries.

**Nerve Supply:** -Median and ulnar nerves.

**EXERCISE** Draw a well labelled diagram showing muscles of lateral and medial aspect of forelimb.



## Practical No. 7

### Study of joints and ligaments of forelimb

The scapula is dorsally attached to the region of the withers by means of muscle only (**Synsarcosis**). The movement of the shoulder on the chest wall is chiefly rotation around the transverse axis. The joints of the forelimb are:-

#### (A) Shoulder joint:

The scapulo- humeral articulation is formed between the glenoid cavity of the scapula and the head of the humerus, which is twice as extensive as the glenoid cavity.

**Ligaments:** - capsular ligament

**Synovial membrane:** - It lines the deep face of capsular ligament.

**Joint:** -Enarthrosis.

**Movement:-**The joint permits all kinds of movements but flexion and extension are most marked.

#### (B) Elbow Joint/ Cubital Joint:

**Humero- radio – ulnar articulation:** - This joint is formed between the distal extremity of the humerus and the proximal extremities of the radius and the ulna. Being a composite joint, it consists of humero- radial and radio-ulnar articulations.

##### a) Humero- radial articulation:-

**Ligaments:** - 3 ligaments – capsular, medial and lateral.

**Synovial membrane:** - It lines the medial face of the capsular ligament and forms three prolongations.

**Joint:** -Ginglymus.

**Movement:** - Flexion and extension.

**b) Radio –ulnar articulation:** - It is formed between the two facets placed below the sigmoid cavity of the ulna, with the corresponding facets seen on the dorso- posterior aspects of the radius. This is enclosed in the joint capsule of the elbow joint. A synarthrosis is formed between shaft of radius & ulna.

**Ligaments:** - ligaments –capsular, interosseous and two arciform.

Interosseous ligaments are proximal, middle and distal. Arciform ligaments are medial and lateral.

**Joint:** -Amphiarthroses in calf and Synarthroses in adult.

**(C) Carpal Joint:**This is a composite joint formed by the union of two rows of short bones with the distal end of the radius and the ulna, and the proximal end of the metacarpals. It principally consists of three sets of articulations:

a) Radio- ulnar carpal articulation.

b) Inter carpal articulation.

c) Carpo- metacarpal articulation.

**(i) Common Ligaments:** - Dorsal capsular ligament, volar capsular ligament, medial carpal ligament, lateral carpal ligament.

**Joint:** -Arthrodia

**Movement:** - Principal movement is between the radio–ulnar carpal articulation .The movements are flexion and extension.

**(ii) Special ligaments:-**

**1. Radio –ulnar carpal articulation:** - It is a diarthroidal joint formed between the distal extremity of the radius and ulna, and the bones of the proximal row of the carpus. It is bound by two oblique and three posterior ligaments.

**2. Proximal carpal articulation:** - Here the 4 bones of the proximal row of the carpus meet each other by apposing facets to form arthrodiar joints. They are connected by 3 anterior, 2 posterior and 3 interosseous ligaments.

**3. Inter carpal articulation:** - It is a diarthroidal joint formed between the proximal and distal row of the carpal joint .It is bounded by 2 oblique and 3 posterior ligaments.

**4. Distal carpal articulation:** - This is an arthrodiar joint formed between the bones of the distal row of the carpus. The joint is held by an anterior and an interosseous ligament.

**5. Carpo- metacarpal articulation:** - It is an arthrodiar joint formed between the bones of the distal row of the carpus and the proximal extremity of the meta carpal bone. It is bounded by 2 anterior, 2 posterior and 2 interosseous ligaments. The accessory carpal is held by 2 anterior and one posterior ligament.

**Synovial membrane:** - Has 3 synovial membranes. The radio- ulnar carpal sac lubricates the radio- ulnar carpal joint. The intercarpal sac lubricates the intercarpal joint and the carpo- metacarpal sac lubricates the carpo – metacarpal articulations.

**Movement:** Flexion and extension in radio- ulnar carpal and intermediate carpal joint. Carpo- metacarpal joint permits slight gliding movement.

**Inter metacarpal articulation:-**

There is only one inter metacarpal articulation .The rudimentary lateral small metacarpal bone articulates with the large metacarpal bone at the postero –lateral aspect. It forms a diarthroidal joint between the articular facets of the two bones. Extension of the synovial sheath from the corpo metacarpal sac covers the articular surfaces. An amphiarthrodiar joint is formed between the apposing surfaces of the bones.

**Fetlock Joint:-** There are two such joints for each limb. The joint is formed by the condyles on the distal extremity of the large metacarpal bone and the proximal extremity of the first phalanx and the two proximal sessamoids.

**Ligaments:-**

- (i) Capsular ligament.
  - (ii) Collateral ligaments - lateral and medial
  - (iii) Sessamoidean ligament- Superior sessamoidean (suspensory) inter- sessamoidean, collateral sessamoidean& distal sessamoidean.
- Metacarpal –Phalangeal articulation: Ginglymus

Movements – Flexion and extension  
Sessamoidean articulation: Arthrodia  
Movement: Gliding

**Proximal inter-phalangeal articulation / Pastern Joint:**-Each limb has two such articulations. Each of the latter is formed between as the distal extremity of the first phalanx and the proximal extremity of the 2<sup>nd</sup> phalanx. The articular surface of the 2<sup>nd</sup> phalanx is glenoid while that of the first phalanx is condyloid

**Ligaments:** - Capsular ligament, collateral ligaments- lateral and medial, Volar ligaments- central and lateral.

**Synovial membrane:** -It lines the capsular and lateral ligaments.

**Joint:**-Ginglymus

**Movement:** - Flexion and extension.

**Distal interphalangeal articulation / Coffin joint:**-There are two distal interphalangeal articulations in each limb. Each is formed between the distal end of the 2<sup>nd</sup> phalanx and the proximal end of the 3<sup>rd</sup> phalanx with the distal sesamoid bone behind.

**Ligaments:** - capsular, anterior elastic, collateral – medial & lateral cruciate, superior and inferior navicular and interdigital - superior and inferior ligaments.

**Joint:** -Ginglymus.

**Movement:** - Flexion and extension.

**Carpal sheath:-**

The carpal sheath or canal is formed by the volar capsular ligament in front and by the volar annular ligament behind, which extends from the posterior border of the accessory carpal to the medial aspect, blending with the medial ligament of the carpus. The canal is lined by the synovial membrane.

**EXERCISE:** Draw a well labelled diagram of shoulder joint, elbow joint and carpal joint of ox.



## Practical No. 8

### Study of major blood vessels and lymph nodes of forelimb

Subclavian artery after giving off intra-thoracic branches continue as **Axillary artery** and supply branches to forelimb. It continues distally over the medial surface of arm. At the level of teres tuberosity its name is changed to **Brachial artery** and below the elbow joint it is known as **Median artery**. The main collateral branches of **Axillary artery** are as following:-

Arteries	Structures supplied
1. External thoracic artery -	
2. Supra scapular artery -	
3. Sub scapular artery -	
(a) Caudal circumflex humeral artery -	
(b) Thoraco-dorsal artery -	
(c) Circumflex artery of the scapula -	

After the sub scapular artery is given off the Axillary artery is continued as **Brachial artery** of the arm region. The collateral branches are -

Arteries	Structures supplied
1. Cranial circumflex humeral artery -	
2. Deep brachial artery -	
3. Collateral ulnar artery -	
4. Transverse cubital artery -	
(a) Proximal branch (Bicipital artery) -	
(b) Distal branch -	
5. Common interosseous artery-	

The **common interosseous artery** is the last branch of brachial artery, distal to the elbow joint. Close to the proximal interosseous space, this artery divides into cranial and caudal interosseous artery.



a) **Cranial interosseous artery:** It is the distal continuation of the common interosseous artery. At the distal half of the forearm, it divides into dorsal and palmar branch.

The **dorsal branch** contributes to the dorsal carpal rete. At the distal end of the forearm it gives a **palmar branch** through the distal interosseous space. The latter divides again into superficial and deep branch. The superficial branch anastomoses with the collateral ulnar artery and the deep branch assist in the formation of palmar carpal rete.

b) **Caudal interosseous artery:** it is very slender and often vascularizes the superficial and deep digital flexors.

**Median artery:** The median artery is the distal continuation of the brachial following the origin of the common interosseous artery. At the proximal third of the forearm it gives off muscular branch which supplies to the flexor muscles. At the middle of the forearm region the median artery gives off **radial** and **ulnar** artery.

a) **Radial artery:** It gives off a strong branch at distal 1/3rd of the forearm called **dorsal carpal branch** which supply the dorsomedial aspect of the carpus and it forms the dorsal carpal rete. From this vascular network arises a small delicate vessel called **dorsal metacarpal artery III**, which descends in the longitudinal groove on the dorsal surface of the metacarpal bone. It gives proximal and distal perforating branch which joins the **proximal and distal deep palmar arch**. After that, it descends over the dorsal aspect of the fetlock joint as **dorsal common digital artery III**, which at the level of the middle of the 1st phalanx, gives off **dorsal proper digital artery III** and **dorsal proper digital artery IV** which goes to 3rd and 4th digits, respectively. After giving these above branches, the dorsal common digital artery III descends through the interdigital space and finally opens in the palmar common digital artery III.

b) **Ulnar artery:** In the palmar aspect the ulnar artery joins with the anastomotic branch from the distal deep palmar arch and form the **palmar common digital artery III**. It descends distally and divides into **palmar proper digital artery III and IV** at the level of fetlock joint which supplies to the third and fourth digits, respectively. Now, after giving the two branches the palmar common digital artery descends through the interdigital space and joins the **dorsal common digital artery III**.

**EXERCISE** Draw a well labelled diagram showing blood supply of forelimb.



## **To study the Lymphatic System**

The lymphatic system is composed of lymph vessels and glands which are connected with the venous part of the blood vascular system.

**Lymph:** It is a clear intercellular fluid that is accumulated in the intercellular spaces or tissue spaces. Components of the lymphatic system:

- a) Lymphatics (small/large)
- b) Lymph nodes
- c) Major lymphatic ducts

**Lymphatic vessels:** These are the vessels either than blood vessels that carry the tissue fluid or lymph to the venous blood. These are very delicate structures and are present in all parts of the body except in the nervous system.

**Lymphatic glands/lymph nodes:** These glands are ovoid, spherical or discoid bodies of medium consistency, grey, rosy or red coloured, and sometimes quite black. They intercept the course of the lymphatic vessels at several points. Their number is considerable and they are rarely single, but most frequently are collected in groups along the blood vessels. The number of lymph nodes is variable, but these are constantly found in certain areas of the body as axilla, inguinal region, mesentery, pre scapular area etc.

**Lymphocentre:** This term is applied to a particular lymph node or a group of lymph nodes which are constantly present in a particular area of the body in a particular species of animal e.g. parotid lymphocentre for parotid lymph node, mandibular lymphocentre for mandibular and pterygoid lymph nodes.

### **Location of lymph nodes of forelimb**

1. **Prescapular L.N.:** It is embedded in fat above shoulder joint.
2. **Axillary L.N.:** It lies behind shoulder joint near teres major.

## Practical No. 9

### To study the Nerves supplying Forelimb

**Brachial plexus:** It is formed by the anastomosis of ventral branches of the last three cervical (C6 C7 and C8) and 1st and 2nd thoracic (T1 and T2) spinal nerves. It appears as a thick, wide band between the two parts of the scalenus muscle and covered by subscapularis muscle. The branches originating from this plexus go for the most part to the thoracic limb, but some are distributed to on the chest wall. The various branches of nerves originating from the brachial plexus are 12 pairs. They are:

- 1. Supra scapular nerve:** It is usually derived from the 6<sup>th</sup> and 7<sup>th</sup> cervical components of the brachial plexus. It passes ventrolaterally and furnishes the supraspinatus, subscapularis and infraspinatus muscles.
- 2. Subscapular nerves:** They usually derive their fibers from the ventral branches of the 6<sup>th</sup> and 7<sup>th</sup> cervical nerves. They are usually two in number and innervate the subscapularis muscle.
- 3. Pectoral or anterior thoracic nerve:** They are formed by the ventral branches of the 7<sup>th</sup> and 8<sup>th</sup> cervical components of the brachial plexus. The caudal pectoral nerves supply the deep pectoral and the cranial pectoral nerves supply the superficial pectoral muscle.
- 4. Musculo cutaneous nerve:** It derives its fibers chiefly from the 6<sup>th</sup>, 7<sup>th</sup> and 8<sup>th</sup> cervical components of the brachial plexus behind the supra scapular nerve. It descends downward in front of median nerve and dips in between the two divisions of coracobrachialis and gives a branch to it. Finally it enters in the biceps brachii.
- 5. Axillary nerve:** It derives its fibers from the 7<sup>th</sup> and 8<sup>th</sup> cervical roots of the brachial plexus. It runs downward and backward caudal to the shoulder joint, reaches the deltoideus muscle and divides into several branches to supply the deltoideus, teres major, teres minor and subscapular muscles.
- 6. Radial nerve:** It is thickest of all branches of the brachial plexus. It derives its fibers entirely from the ventral branches of the 7<sup>th</sup> & 8<sup>th</sup> cervical and 1<sup>st</sup> thoracic spinal nerves. It passes downward parallel to brachial artery and disappears in front of the triceps and terminates in the musculospiral groove. During its course in the arm it gives collaterals to the triceps brachii, tensor fasciae antebrachii and anconeus muscles. On reaching the flexor surface of the elbow joint it gives certain muscular and cutaneous branches, and divides into a superficial and deep branch.

The superficial branch emerges between the brachialis and extensor carpi radialis and, near the lateral head of triceps, it detaches a long slender branch. It then continues distally along the dorsal aspect of the carpus. Slightly proximal to the fetlock joint it divides into dorsal common digital nerve II and III.

The dorsal common digital nerve II gives branches to second accessory digit and continues on the abaxial side of the third digit as the dorsal proper (abaxial) digital nerve III.

The dorsal common digital nerve III divides into dorsal proper digital nerves III and IV which descends along the axial (interdigital) side of the principal digits.

The deep branch passes between the brachialis and the extensor carpi radialis and divides in a variable manner into several muscular branches to innervate the all extensor group of muscles of the forearm at its craniolateral aspect along with the ulnaris lateralis muscle.

- 7. Ulnar nerve:** It derives its fibers from the ventral branches of the 8th cervical and 1st and 2nd thoracic spinal nerves. It descends over the medial face of the axillary artery in company with the median nerve. Slightly proximal to the elbow joint it detaches the caudal cutaneous antebrachial nerve. It then descends between the flexor carpi ulnaris and ulnaris lateralis and divides into dorsal and palmar branches. In the forearm region it gives muscular branches to all flexor muscles and elbow joint.

The dorsal branch courses along the dorsolateral aspect of the metacarpus and continues as the dorsal common digital nerve IV. Near the fetlock joint it gives branches to lateral accessory (5th) digit and continues as the dorsal proper (abaxial) digital nerve IV.

The palmar branch gives a deep branch to the interosseus muscle and a superficial branch called palmar common digital nerve IV. The common digital nerve IV continues distally as the palmar proper (abaxial) digital nerve IV after giving branch to the lateral accessory digit.

- 8. Median nerve:** It derives its fibers chiefly from the ventral branches of the 8th cervical and, 1st and 2nd thoracic spinal nerves. It runs downward, passes between the flexor carpi radialis and superficial digital flexor, reaches the lower third of the metacarpus and divides into medial and lateral branches. It gives muscular branches to the flexor muscles and joint capsule of elbow joint.

The medial branch divides into palmar common digital nerve II and the palmar (axial) digital nerve III. Near the fetlock joint the palmar (axial) digital nerve III gives branches to the medial accessory digit and continues along the axial surface of the third digit. The palmar common digital nerve II, near the fetlock joint, divides into the palmar proper digital nerve II and palmar (abaxial) proper digital nerve III.

The lateral branch divides into palmar (axial) digital nerve IV and a communicating branch. The former, after giving branch to the lateral accessory digit, descends along the axial surface of the fourth digit. The communicating branch joins the superficial branch of the palmar branch of the ulnar nerve, constituting the palmar common digital nerve IV, which, near the fetlock joint, divides into the palmar proper digital nerve V and the palmar (abaxial) proper digital nerve IV.

- 9. Long thoracic nerve:** It derives its fibers from the 7th and 8th cervical spinal components of the brachial plexus. It courses laterally between the scaleni muscles in a variable manner without entering the plexus. It is distributed to the serratus ventralis thoracis muscle.

- 10. Thoraco dorsal nerve:** It derives its fibers chiefly from the ventral branches of the 7th and 8th cervical spinal nerves. It is distributed mainly to the latissimus dorsi muscle.

- 11. Lateral/External thoracic nerve:** It arises chiefly from the ventral branches of the 8th cervical and the 1st and 2nd thoracic spinal nerves. It passes backward to the internal face of the long head of triceps. It gives number of branches to deep pectoral muscle. It continues

backward and distributes number of branches to abdominal cutaneous muscle and the skin covering it. It terminates at the flank.

**12. Nerves to teres major:** It is a small nerve arises from caudal aspect of brachial plexus, passes backward and supplies the teres major muscle.

**EXERCISE** Draw a well labelled diagram of brachial plexus of ruminants.

## Practical No. 10

### Study of sites for different nerve blocks, neurectomies in forelimb

#### Nerve blocks

- Temporary blocking of pathways for passage of impulses by injecting local anaesthetic solution resulting in desensitization and paresis in the region controlled by the nerve

#### Neurectomy

- Neurectomy is the division and removal of a piece of nerve

#### Indications

- To remove pain and to improve usefulness of the animal
- Lameness due to chronic conditions
- Splints, ringbone, navicular disease, laminitis (horse)

#### Nerve block and neurectomies in forelimb

##### Median nerve block and neurectomy

- The median nerve passes below the elbow beneath the pronator teres
- It then runs down along the forearm between the radius and flexor carpi radialis muscle
- Median nerve supplies pronator teres, flexor carpi radialis, superficial digital flexor, humeral and radial heads of deep digital flexor muscles
- Site : Below the medial tuberosity of the radius at the groove between caudal border of the radius and flexor carpi radialis muscle

##### Ulnar nerve block and neurectomy

- At the lower one third of the forearm this nerve lies relatively superficial between the flexor carpi ulnaris and ulnaris lateralis muscle
- Ulnar nerve supplies the flexor carpi ulnaris, superficial digital flexor and ulnar head of deep digital flexor
- Site : A few inches above accessory carpal

##### Volar nerve block and neurectomy

- The volar or metacarpal nerves are terminal branches of the median nerve
- The lateral volar nerve merges with the deep branch of the ulnar nerve
- The medial volar nerve is accompanied by the medial volar metacarpal artery, the lateral volar nerve is accompanied by the lateral volar metacarpal artery
- Each volar metacarpal nerve continues as respective volar abaxial digital nerve where as volar common digital nerve is formed by union of middle branches of median nerve

#### Site

- *High volar block* : 5 to 7 cm above the fetlock in the depression between suspensory ligament and deep flexor tendon both on medial and lateral aspects
- *Low volar block* : Midway between the fetlock and coronet in between deep digital flexor and superficial digital flexor both on medial and lateral aspects

**EXERCISE** Draw a well labelled diagram of sites for various nerve blocks of forelimb.





**PARALYSIS:** Paralysis is the loss of function of muscles i.e. their inability to contract in response to normal stimuli.

**1. Supra-scapular nerve paralysis (Sweeny)**

**It is most anterior of all the nerves of the plexus.** It passes forward, downwards & outwards; gains space between supraspinatus and subscapularis muscle, turns around the lower 4<sup>th</sup> of anterior border of scapula, gains supraspinous fossa and gives branches to supraspinatus muscle. It then continues backwards under acromion process, passes into infraspinous fossa and terminates here.

Because of its close association with bone, it is vulnerable to traumatic damage. It causes “*sweeny*” in horses. Scapular spine becomes sharply defined.



**2. Radial nerve paralysis (capped elbow)**

Radial nerve is the largest nerve of brachial plexus. It passes downwards and outwards along the musculospiral groove of the humerus over brachialis. It supplies the triceps, extensors of the carpus and digits.

Radial paralysis is more commonly seen in the horses and rarely in cattle and dog. The radial paralysis can be induced experimentally few cm above the elbow by incising through skin and lateral head of triceps where the nerve is passing over the brachialis. If branch supplying to triceps is only paralysed the elbow is flexed. If total nerve is paralysed elbow, carpus, fetlock, pastern and coffin joints are in flexed state since extensors of carpus and digits lose their action and flexors take upper hand

## UNIT III

### Practical No. 1

**To study the skull of Ox and to compare the same with Horse, Dog and Fowl**

#### **The Skull**

**Ox:** The bones of the skull are divided into cranial & facial groups

**Cranial Bones:** - Parietal, Inter-parietal, Occipital, Sphenoid, Ethmoid, Temporal and Frontal.

**Facial Bones:** - Nasal, Premaxilla, Maxilla, Palatine, Pterygoid, Lacrimal, Malar or zygomatic, Turbinates, Vomer, Mandible and Hyoid.

**Unpaired / Single bones:** Occipital, Sphenoid, Ethmoid. Vomer. Mandible and Hyoid.

#### **Sinuses of the skull (Para nasal sinuses)**

1. Frontal sinus
2. Sphenoidal sinus
3. Maxillary sinus
4. Palatine sinus
5. Ethmoidal sinus

**Cranial cavity:** It is an a void cavity situated on the dorsal aspect of the nasal sinus lodging the brain with meninges and vessels .The cranial cavity is more or less rounded being elongated posteriorly. The ventral extremity is blind while the dorsal terminates in a large opening, the **foramen magnum**. It presents for description, roof, floor, lateral walls and two extremities. **The roof** is formed by the inner table of the frontal bone.**The lateral walls** are formed by the ventral part of the parietal, temporal, frontal and the orbital wings of the sphenoid. The floor is formed by the basilar process of the occipital and the sphenoid.

#### **Fossae of the skull:**

**1. Orbital fossa:** The orbital fossa is a deep depression on the surface of the skull, situated on its dorsa-lateral aspect .It is intended for the lodgment of the eyeball and its accessory structures.

**2. Pterygo –palatine fossa:** The Pterygo-palatine fossa which is the posterior extension of the orbital fossa is formed behind and below the level of the orbit, and is very large and well defined.

**3. Temporal Fossa:** The temporal fossa is placed above and behind the orbit. It extends obliquely downwards and outwards on the side of the cranium, being quadrilateral in outline.

**Skull of Horse:**

1. The skull is long and four sided.
2. The foramen lacerum is extensive.
3. The cornual process is absent.
4. Zygomatic process meets malar as well as supraorbital process.
5. Inter parietal is centrally placed and considered as a single bone.
6. Parietal bones take part in the formation of the roof of cranial cavity.
7. Premaxilla presents six alveolar sockets for upper incisors.
8. At the junction between maxilla and premaxilla, there is a alveolus for canine tooth.

**Skull of Dog:**

1. The skull is oval elongated in shape but varies highly from breed to breed.
2. Basioccipital bone joints with bulla tympani.
3. Horn core is absent.
4. Zygomatic process is highly curved.
5. Interparietal bone fuses with occipital before birth.
6. Parietal bones take part in the formation of the roof of cranial cavity.
7. Premaxilla has sockets for incisors. The alveolus for canine tooth is well developed.
8. The orbital rim is incomplete.

**Skull of Pig:**

1. The skull is elongated in shape.
2. Basilar part of occipital bone is hexagonal in shape and depressed.
3. Orbital ring is not complete.
4. Canine teeth are well developed.
5. Paramastoid process is long and extended downwards.
6. Cranial cavity is comparatively small.

**Skull of Fowl:**

1. Most of the bones are fused.
2. Upper jaw is movable due to the presence of nasal frontal hinge.
3. Orbit is large.
4. Occipital condyle is single.
5. Teeth are absent.
- 6.

**EXERCISE:** Draw a well labelled diagram of skull (Dorsal and ventral view) of different domestic animals.



## Practical No. 2

### To study the mandible of ox and to compare the same with Horse, Dog, Pig and Fowl

**Ox:** To be described by the student (only the salient features).

**Horse:**

1. The fusion of the halves of the body is complete.
2. The alveolar border carries 6 deep alveoli for the incisors. A little behind the corner alveolus on either side is the alveolus for the canine tooth (in the males).
3. The inter mandibular space is narrow.
4. The mental foramen is placed further backwards than ox.
5. Occasionally, there is a small alveolus in front of the first molar for the inconstant wolf tooth.
6. The coronoid process is thinner and is rounded at its free end.

**Dog:**

1. The two halves of the body do not fuse completely.
2. The body carries six alveoli for the incision end two for the incision and two for the canine teeth.
3. The two rami diverge more enclosing a large inter mandibular space.
4. The alveoli carry seven alveoli for the lower cheek teeth.
5. Inter dental space is very short.
6. The mental foramina are two or three, usually placed one behind the other.
7. On the external surface of the ramus, there is a deep, masseteric fossa which extends up to the coronoid process.
8. From the middle of the posterior border, projects a strong angular process which is directed backward and outwards.

**Pig:**

1. The fusion of the two halves of the body is complete.
2. The bodies are joined at the symphysis and diverge at a greater angle than in the horse or ox.
3. Internally, dorsal to the angle formed by the bodies is a pair of medial mental foramina. On the labial surface there are lateral mental foramina.
4. The alveolar border of the incisive part presents six alveoli for the incisor teeth and a little further caudal two large cavities for the canine teeth.
5. The lateral surface of ramus is roughly flattened, with the exception of the dorsal half, which is concave for the masseteric fossa.
6. The coronoid process continues the ramus dorsally. It is small and thin edged and is separated from the condylar process by a wide notch the mandibular incisure.

**Mandible of Fowl:**

1. Each half of mandible is formed by the fusion of five bones.
2. The largest and most rostral of the bones of the lower jaw is the dentary, which forms a mandibular symphysis distally. Other components may include a splenial, angular, surangular, pre articular and the articular, which articulates with the condyles of the quadrate.
3. There is usually a mandibular foramen caudal to the dentary.

**EXERCISE:**

1. Describe the salient features of the mandible of ox.





## Practical No. 3

### Demonstration of cervical vertebrae of ox and comparison with Horse, Dog, Pig and Fowl

The whole vertebral column may be divided into 5 regions –

1. **Cervical vertebrae:** - constitutes the skeleton of the neck.
2. **Thoracic vertebrae:** - constitutes the skeleton of the back.
3. **Lumbar vertebrae:** - constitutes the skeleton of the loin.
4. **Sacral vertebrae:** - constitutes the skeleton of the croup.
5. **Coccygeal vertebrae:** - constitutes the skeleton of the tail.

The vertebral formulae of various species of animals are-

**Ox:** C<sub>7</sub> T<sub>13</sub> L<sub>6</sub> S<sub>5</sub> Cy<sub>18-20</sub>

**Horse:** C<sub>7</sub> T<sub>18</sub> L<sub>6</sub> S<sub>5</sub> Cy<sub>15-21</sub>

**Dog:** C<sub>7</sub> T<sub>13</sub> L<sub>7</sub> S<sub>3</sub> Cy<sub>19-23</sub>

**Pig:** C<sub>7</sub> T<sub>14-15</sub> L<sub>7</sub> S<sub>4</sub> Cy<sub>18-24</sub>

**Rabbit:** C<sub>7</sub> T<sub>12-13</sub> L<sub>6-7</sub> S<sub>4</sub> Cy<sub>14-18</sub>

**Fowl:** C<sub>14</sub> T<sub>7</sub> L<sub>+</sub> S<sub>14</sub> Cy<sub>4-9</sub>

**Typical vertebra:** A typical vertebra consists of the following structures-

1. Body:
2. Arch/Neural arch:
3. Processes:
  - i. Articular or oblique processes:
  - ii. Transverse processes:
  - iii. Spinous processes:
  - iv. Ventral spinous processes:
  - v. Mamillary processes:
  - vi. Accessory processes:

### Cervical Vertebrae

#### Atlas

**Ox:** To be described by the student (only the salient features)

#### Horse:

1. The wing slopes downwards and outwards.
2. Besides the alar and intervertebral foramina, there is a foramen transversarium at the posterior part of the wing.
3. The posterior articular surfaces are saddle shaped.

**Dog:**

1. Ventral arch is narrower from before backward, and bears a small tubercle posteriorly.
2. Dorsal surface of dorsal arch is strongly convex and rough centrally.
3. An alar notch is present on the anterior border instead of alar foramen.
4. Foramen transversarium is present.

**Fig:**

1. The dorsal tubercle of the atlas is large.
2. The transverse process (wing) is flattened and bears a caudal tuberosity.
3. The transverse foramen is very small or absent.

**Fowl:**

1. The atlas is ring like.
2. The ventral arch presents interiorly a concave articular area for the single occipital condyle.

**Axis**

**Ox:** To be described by the student (only the salient features)

**Horse:**

1. The body is large.
2. The dens or odontoid process is longer, narrower and more pointed.
3. The transverse process is thinner.

**Dog:**

1. The dens/odontoid process is rounded, very long and reaches almost the occipital bone.
2. The anterior articular areas are condyloid and very oblique.

**Fig:**

1. The axis has a large spinous process which is directed dorsally and caudally.
2. The dens is a thick cylindrical rod.
- 3.

**Fowl:**

1. The anterior articular processes are present and articulate with the facets on the
2. Posterior aspects of the dorsal arch of atlas.
3. The dens articulate with the occipital condyle.
4. The transverse processes are absent.

**Cervical vertebrae (from 3<sup>rd</sup> to 5<sup>th</sup> cervical vertebrae)**

**Ox:** to be described by the student (only the salient features).

**Horse:**

1. A continuous plate of bone unites the anterior and posterior oblique processes in the 5<sup>th</sup>, but this plate extends only three fourth the distance forwards the posterior articular process in the 4<sup>th</sup>, and only half way in the 3<sup>rd</sup>.
2. The spines are less developed.

**Dog:**

1. The bodies are relatively longer and are compressed dorso-ventrally.

**Pig:**

1. The cervical vertebrae are short and wide.
2. The transverse processes divide into two branches.
3. The spinous processes increase in height from the 3<sup>rd</sup> to the last. The cranial ones are inclined caudally and the caudal ones cranially.

**Fowl:**

The bodies of these vertebrae are rod like. The anterior extremity of each vertebra is concave from side to side and convex from above downward. The transverse processes arise from under the anterior articular processes and are prolonged behind the spicules of bone called styloid processes.

**6<sup>th</sup> cervical vertebra**

**Ox:** To be described by the student (only the salient features).

**7<sup>th</sup> Cervical Vertebrae**

**Ox:** To be described by the student (only the salient features).

**Horse:-**

1. The spine is flattened triangular process and much smaller than that of the ox.

**Dog:**

1. It is shorter.

**Pig:**

1. It can be recognized by the great length of its spinous process (approximately 10 cm in the adult.)
2. Ventral plate of the transverse process is absent.

**EXERCISE:**

Describe the salient features of the atlas, axis, 6<sup>th</sup> & 7<sup>th</sup> cervical vertebrae and draw a well labelled diagram of all these vertebrae of ox, horse, dog, pig and fowl.

## Practical No. 4

### Dissection of muscles of face, mastication, tongue, pharynx, soft palate, hyoid, larynx, eye and ear

#### To study muscles of the Head

**Cutaneous muscle:** - It is a thin muscle layer developed in the superficial fascia.

#### a) Muscles of the lips and cheeks:

- 1. Orbicularis oris:** - It is a sphincter muscle which is located around the anterior opening of the mouth.  
**Action:** - To close the lips and help in mastication.
- 2. Levator nasolabialis:** This is an extensive muscle and is continuous above the frontalis.  
**Origin:** - Frontal and nasal bones.  
**Insertion:** - Upper lip and lateral part of nostril.  
**Action:** - to elevate the upper lip and dilate the nostrils.
- 3. Levator labii superioris proprius:** - This is a narrow muscle extending from the facial tuberosity to the upper lip.  
**Origin:** - Facial tuberosity.  
**Insertion:** - By several tendons to the upper lip.  
**Action:** - To elevate the upper lip and to draw it to sides.
- 4. Dilator naris lateralis:** It is a narrow band like muscle placed between muscles No.3 and 1 & 2 muscles.  
**Origin:** - Facial tuberosity.  
**Insertion:** - Lateral wing of the nostrils.  
**Action:** - To dilate the nostrils.
- 5. Depressor labii superioris:** It is situated below the proceeding muscle.  
**Origin:** - Facial tuberosity.  
**Insertion:** - Muzzle and upper lip by several tendon.  
**Action:** - To compress the upper lip.
- 6. Zygomaticus:** It is a strong muscle that extends upon the surface of the masseter up to the zygomatic arch ventral to the eye.  
**Origin:** - Temporal process of the zygomatic bone and the masseteric fascia.  
**Insertion:** - Angle of the mouth to blend with the orbicularis oris muscle.  
**Action:** - To retract and raise the angles of the mouth.
- 7. Incisivus superior:** - It consists of a group of muscle fibres extending from the anterolateral angle of the Premaxilla to the deep surface of the upper lip.  
Its action is to pull the lip towards the Premaxilla.

8. **Incisivus inferior:** It is situated at the lower lip.  
**Origin:-** Body of mandible at the level of 2<sup>nd</sup> incisor tooth.  
**Insertion:** - Lower lip.  
**Action:** - To elevate the chin.
9. **Mentalis:** Lies in the chin ventral to the body of the mandible.  
**Origin:** - Body of mandible on either sides of the mandibular symphysis.  
**Insertion:** - Skin of the chin.  
**Action:** - To wrinkle the skin and pull it forward.
10. **Buccinator:** This muscle lies in the lateral wall of the mouth.  
**Origin:** -Alveolar border of the mandible and maxilla.  
**Insertion:-**Angle of mouth blending with the orbicularis.  
**Action:** - Helps in mastication.
11. **Depressor labiiinferioris:** it lies on the lateral surface of the ramus of the mandible, along the ventral border of the buccinator.  
**Origin:** -Alveolar border of the mandible behind the last cheek tooth.  
**Insertion:-**Lower lip.  
**Action:** - To depress the lower lip

**(b) Muscles of the nostrils:-**

1. **Levator nasolabialis:** already described.
2. **Dilator naris lateralis:** already described.
3. **Dilator naris apicalis:** It is located in the premaxilla.  
**Origin:** -Body of the premaxilla.  
**Insertion:-**Medial wing of the nostril.  
**Action:** - To dilate the nostril.
4. **Lateralis nasi-dorsal part:**  
**Origin:** -Alar cartilage of the nostril body of the premaxilla.  
**Insertion:-**Medial wings of nostrils.
5. **Lateralis nasi-ventral part:**  
**Origin:** - Nasal process of the premaxilla.

**(c) Muscles of the Eye-lids**

1. **Orbicularis oculi:** It is well developed, flat, elliptical sphincter muscle around the eyelids. Its action is to close the eyelids.
2. **Corrugator supercilli:** This muscle raises the upper eyelid and wrinkles the skin.

3. **Malaris:** This is a broad muscle spreading below the lower eye lid over the buccinator and masseter muscles. It is divisible into an anterior part- levatorbuccalis and posterior part- the depressor palpebraeinferioris.
4. **Levatorpalpebraesuperiorus:** it is situated within the orbit.
  - Origin:** -Pterygoid crest, opposite the optic foramen.
  - Insertion:-** Upper lid.
  - Action:** - To raise the upper lip.

**Muscles of eye ball:** There are 4 straight muscles, 1 retractor and 2 oblique muscles are there  
**The straight muscles are 1) Rectus dorsalis, 2) Rectus Ventralis, 3) Rectus medialis and 4) Rectus lateralis.**

**Origin:** - All the muscles arise from around the optic foramen. They pass along the corresponding parts of eyeball.

**Insertion:** - Forepart of the sclera by fine aponeurotic tendons.

**Action:** - The dorsal and ventral recti rotate the eyeball about a transverse axis. The medial and lateral rotate the eyeball along a ventricle axis .All the four muscles acting together will retract the eyeball.

5. **The retractor oculi:** - is the only retractor muscle that is enclosed within the recti muscle and it envelops the optic nerve.
  - Origin:** - Around the optic foramen.
  - Insertion:** - To the posterior part of the sclera
  - Action:** - To retract the eyeball into the orbit.

**6. The Dorsal oblique muscle:**

**Origin:-** Near the ethmoidal foramen.

**Insertion:-**It is inserted to the sclera between the dorsal and lateral recti muscles.

**Action:** - To rotate the eye ball along a longitudinal axis. It raises the lateral edge of the pupil.

**7. The Ventral oblique muscle:**

**Origin:** - Depression behind the lacrimal fossa.

**Insertion:** - Into the sclera near the insertion point of the lateral rules muscle .It is inserted to the sclera between the dorsal and lateral recti muscles.

**Action:** - To rotate the eye ball along a longitudinal axis. It raises the lateral edge of the pupil.

**(d) Mandibular Muscles (Muscles of Mastication)**

1. **Masseter:** This muscle is situated on the lateral face of the broad part of the ramus of the mandible.
  - Origin:** -Zygomatic arch, facial crest and facial tuberosity.

**Insertion:** - Lateral face and posterior border of the ventral part of the ramus of the mandible.

**Action:** - To close the jaws and to move the mandible forward and upward.

2. **Temporalis:** it is situated on the temporal fossa.

**Origin:** - Rough part of the temporal fossa.

**Insertion:** - Coronoid process of the mandible.

**Action:** - To raise the lower jaw.

3. **Pterygoideusmedialis:** This muscle is situated on the medial face of the ventral ramus of the mandible opposite the masseter muscle.

**Origin:** - Palatine and pterygoid crest of the sphenoid bone

**Insertion:** - Medial surface of the vertical ramus of the mandible.

**Action:** - To raise the lower jaw and acting alone to assist in the lateral movement of the jaw.

4. **Pterygoideuslateralis:** It is a small muscle situated lateral to the upper part of the preceding muscle.

**Origin:** - Pterygoid process of the sphenoid bone.

**Insertion:** - Medial face of the condyle and neck of the mandible.

**Action:** - To draw the jaw forward and acting alone to move it to the opposite side.

5. **Digastricus:** It is a long muscle extending from the mastoid process to the medial face of the horizontal ramus.

**Origin:** - Para mastoid process.

**Insertion:** - Medial face of the condyle and neck of the mandible.

**Action:** - To depress the lower jaw.

#### (e) Muscles of the external Ear

There are two types of muscles – Extrinsic and intrinsic

##### Extrinsic Muscles:

1. **Parotido-auricularis:** it is thin, wide muscle situated on the parotid salivary gland. It is wide below and narrow above.

**Origin:** - Fascia on the lower part of parotid salivary gland.

**Insertion:** - Conchal cartilage.

**Action:** - To incline the ear downwards and backwards.

2. **Perioto-auricularis externus:** it is a thin muscle that covers the temporalis.

**Origin:** - Frontal crest parietal and occipital bones.

**Insertion:** - Anterior aspects of concha.

**Action:** - To adduct the concha.



**3. Cervicoauricularis:**

**Origin:** - Ligamentum nuchal and cervical fascia.

**Insertion:**-Medial face of the base of the concha.

**Action:** - To adduct the concha.

**4. Parietoauricularis internus:**

**Origin:** - Parietal bone behind the frontal eminence.

**Insertion:**-Medial face of the concha.

**Action:** - To adduct the ear.

**5. Zygomatico - auricularis:** It is made up of two muscles.

**Origin:** - Zygomatic process of the squamous temporal bone.

**Insertion:**-Base of concha

**6. Mastoido - auricularis:** it is a very thin muscle.

**Origin:** - External auditory process and annular cartilage.

**Insertion:**-Base of concha

**Intrinsic Muscles:**

**1. Scutuloauricularis externus:**

**Origin:** -The outer face of the scutiform cartilage.

**Insertion:**-Medial part of the base of concha.

**2. Scutuloauricularis internus:-**

**Origin:** - Internal face of the scutiform cartilage.

**Insertion:**-Anterior aspect of the base of concha.

**Muscles of the hyoid apparatus:** There are 8 muscles-

**1. Mylo-hyoideus:** They are two muscle and forma base for the tongue.

**Origin:** - Medial face of the mandible.

**Insertion:** - Lingual process of the hyoid bone.

**Action:** - To raise the tongue and hyoid bone.

**2. Stylohyoideus:**

**Origin:** - Muscular angle of great cornu of hyoid bone.

**Insertion:**-lateral extremity of body of hyoid bone.

**Action:** - To draw the tongue and the hyoid bone upwards and backwards.

**3. Genio- hyoideus:**

**Origin:** - Medial face of the ramus of mandible close to the symphysis.

**Insertion:** - Body of hyoid.

**Action:** - To draw the tongue and the hyoid.

**4. Occipito-hyoideus:**

**Origin:** - Paramastoid process.

**Insertion:** - Muscles angle of the stylohyoid.

**Action:** - To draw the great cornu backward.

**5. Keratohyoideus:**

**Origin:** - Posterior border of small cornu.

**Insertion:** - Dorsal border of the thyroid cornu.

**Action:** - To raise the larynx.

**6. Hyoideustransverus:** It is a small unpaired muscle. It raises the root of the tongue.

**7. Sternothyrohyoideus:** It is a long, slender muscle attached to the ventral surface of trachea.

**Origin:** - Cariniform cartilage of the sternum.

**Insertion:** - Lingual process of the hyoid bone.

**Action:** - To depress the hyoid bone the base of the tongue in deglutition.

**8. Omo- hyoideus:** This is a thin, ribbon like muscle.

**Origin:** - The sub scapular fascia close to the shoulder joint.

**Insertion:** - Lingual process of the hyoid bone.

**Action:** - To retract the hyoid bone and the tongue.

**Muscles of the tongue:**

The lingual muscle are extrinsic intrinsic. The extrinsic muscles are present inside the tongue and they run in all directions.

**Extrinsic Muscles:-** There are 3 muscles.

**1. Stylo-glossus:** It is along muscle present on the ventro lateral aspect of the tongue.

**Origin:** - Great cornu of the hypoid bone.

**Insertion:-** Tip of the tongue.

**Action:** - To retract the tongue and draw it to a side.

**2. Hyoglossus:** It is wide, flat muscle arising from the body of the tongue .It retracts and depresses the tongue.

**3. Genioglossus:** It is wide fan shaped muscle.

**Origin:** - Medial face of the ramus of the mandible.

**Insertion:-** Tip body and root of the tongue.

**Action:** - It retracts, depresses and protracts the tongue.

**Muscles of the soft Palate:** There are 4 muscles:

**1. Palatoglossus:** It is a small muscle.

**Origin:** - Border of the soft palate

**Insertion:** - Root of the tongue.

**Action:** - It narrows the faces.

**2. Tensor palati:**

**Origin:** - Muscles process of petrous temporal bone.

**Insertion:** - Soft palate

**Action:** - It tenses the palate

**3. Levatorpalati:**

**Origin:** - Muscles process of petrous temporal bone.

**Insertion:** - Soft palate

**Action:** - It raise the soft palate and to close the posterior nares during deglutition.

**4. Palatinus:** It is a small, elongated brought red muscle laying along with its fellow enclosed in the palatine aponeurosis.

**Origin:** - From the posterior border of bony palate.

**Insertion:** - Aponeurosis near the face border of the soft palate.

**Muscles of pharynx:** There are 6 muscles:

**1. Stylo – Pharyngeus:**

**Origin:** - Great cornu of hyoid bone.

**Action:** - It dilates the pharynx.

**2. Plato – Pharyngeus:**

**Origin:** - vertical part of the palatine bone.

**Action:** - It shortens the pharynx.

**3. Pterygo – Pharyngeus:**

**Origin:** - Pterygoid Process.

**Action:** - It shortens the pharynx.

**4. Hyo– Pharyngeus:**

**Origin:** - Thyroid cornu of the hyoid bone.

**Action:** - Constructs the pharynx.

**5. Thyro– Pharyngeus:**

**Origin:** - Lamina of thyroid gland.

**Action:** - Constructs the pharynx.

**6. Crico-Pharyngeus:**

**Origin:** - Lateral part of the arch of the acicoid cartilage.

**Action:** - Constructs the pharynx

**Muscles of larynx:** There are extrinsic and intrinsic muscles.

**Extrinsic Muscles:**

**1. Sterno- thyro- hyoideus:** already described.

**2. Thyro- hyoideus:**

**Origin:** - Thyroid cartilage.

**Insertion:**-hyoid bone.

**Action:** - It draws the pharynx downwards & forwards.

**3. Hyo- epiglotticus:**

**Origin:** - Thyroid bone

**Insertion:** - Epiglottis.

**Action:** - It draws the epiglottis towards the root of the tongue

**Intrinsic Muscles:**

**1. Cricothyroidus:** Lies on the posterior lateral surface of the larynx.

**Origin:** - Cricoid cartilage.

**Insertion:** - Posterior corbus of the thyroid cartilage.

**Action:** - Tense the vocal folds.

**2. Cricoarytenoideus dorsalis:**

**Origin:** - Lamina of cricoid cartilage.

**Insertion:**--Muscular process of the arytenoids cartilage.

**Action:** - Dilates the glottis and abducts the vocal folds.

**3. Cricoarytenoideuslateralis:**

**Origin:** - Upper part of the cricoid cartilage

**Insertion:**--Muscular process of the arytenoids cartilage.

**Action:** - It closes the glottis

**4. Arytenoideus transverses:** It is a unpaired muscle.

**5. Thyro-anytenoideus:**

**EXERCISE 1.** Draw a well labelled diagram of muscles of face.

**2.** Draw a well labelled diagram of muscles of eye ball.





## Practical No. 5

### Dissection of superficial neck muscles

The cutaneous muscle is absent in neck region the cervical muscles can be divided into two groups.

- a) Vento cervical group ( 9 muscles) and
- b) Lateral cervical group( 12 muscles)

#### a) Vento cervical group:

1. **Sterno –cephalicus:** This muscle consists of two divisions mastoideus.

**Origin:** - Both divisions arise together from the manubrium sterni and first costal cartilage. These two divisions are lower close together at their origin and in the lower third of the neck. From the middle they diverse. The sterno- mandibular is the superficial and it forms the lower boundary of the jugular furrow. Sterno- mastoideus is the deeper part.

**Insertion:** - Superficial division is inserted to the anterior border of the masseter muscle

**Action:** - Together to flex the head on the neck.

2. **Sterno- thyro- hyoideus:** This is along slender muscle situated on the ventral face of the trachea.

**Origin:** - Manubrium sterni. The two muscles are very close together at their origin and cover the trachea at the lower third of the neck. About the middle of the neck, each muscle divides into two bands the thyroid and hyoid bands. Hence, in the upper third of the neck the ventral face of the trachea is not covered by any muscle.

**Insertion:**-Thyroid band is inserted to the thyroid cartilage of the larynx and the hyoid band is inserted to the body of the hyoid bone.

**Action:**-To depress the hyoid, larynx and tongue.

3. **Omo- hyoideus:** This is small triangular muscle .extending from the neck to the hyoid bone.

**Origin:**-Transverse process of 3<sup>rd</sup> and 4<sup>th</sup> cervical vertebrae. This muscle passes under the deep face of the brachio- cephalicus and sternsmastoideus muscle obliquely forward.

**Insertion:**-Body of the hyoid bone.

**Action:** - To retract the hyoid bone and root of the tongue.

4. **Scalenus:** This muscle is made up of two divisions dorsal and ventral, between which emerge the roots of the brachial plexus.

**Origin:**-The dorsal part arises from the transverse process of the 4<sup>th</sup> to the 7<sup>th</sup> cervical vertebrae. The ventral part arises from the transverse process of the 4<sup>th</sup> to 6<sup>th</sup> cervical vertebrae.The dorsal part is covered by the serratus thoracis muscle. The ventral part is transversed by the root of the phranic nerves.

**Insertion:** - The dorsal part to the 4<sup>th</sup> rib and the ventral part to the anterior border of the rib.

**Action:** - To flex the neck or incline it laterally.

**5. Rectus capitis ventralis major** (Longus capitis): This muscle extends from the neck to the base occipital bone.

**Origin:** - Transverse process of the cervical vertebrae from the 2<sup>nd</sup> to the 6<sup>th</sup>.

**Insertion:** - Basilar tubercle of the occipital bone.

**Action:** - To flex the head or incline it laterally.

**6. Rectus capitis ventralis minor** (Rectus capitis ventralis): This is a small muscle placed dorsal and medial to the proceeding.

**Origin:** - Ventral surface of the wing of atlas at the exterior side.

**Insertion:** - Basilar tubercle of the occipital bone.

**Action:** - To flex the occipitoatlantal joint.

**7. Rectus capitis posterior:**

**Origin:** - Atlas.

**Insertion:** - Paramastoid process.

**Action:** - To flex the occipitoatlantal joint.

**8. Inter transverse colli:** This occupies the space between the articular and transverse process on the lateral surface of the cervical vertebrae. Origin and insertion are not recognized.

**Action:** - To flex the neck laterally.

**9. Longus colli:**-This is a long muscle extending from the 6<sup>th</sup> thoracic vertebra to the atlas. It is situated in the ventral aspect of these vertebrae. It has got two parts thoracic and cervical parts.

**Origin:** - Bodies of the first – sixth thoracic vertebrae.

**Insertion:-** - The thoracic part is inserted to the bodies and transverse process of the last two cervical vertebrae. The cervical vertebrae and the ventral tubercle of atlas.

**Action:** - To flex the neck.

**(b) Lateral cervical Group:**

**First Layer** -Trapezius cervicalis and Brachiocephalicus (Cleido occipitalis & Cleido-mastoideus)

**Second Layer:**-Omo-transversarius, Rhomboideus cervicalis and Serratus cervicis.

**Third Layer:-**

**6. Solenius:** - It is a triangular muscle.

**Origin:** - The summits of first three or four thoracic spines.

**Insertion:-** Occipital bone, transverse process of first three cervical vertebrae in common with omo- transversarius , cleido- occipitalis and longissimus capitis at atlantis muscle.

**Action:** - To elevate the head & neck or extend them.



#### **Fourth Layer:-**

- 1. Longissimus capitis at atlantis:** -There are two parallel muscular bundles on deep face of the splenius. The upper one, the more medial part is longissimus capitis and overlapped by the lower lateral part. The longissimus atlantis.  
**Origin:** - Transverse processes of the first two thoracic and the articular process of the cervical vertebrae except the first two or three.  
**Insertion:** - Mastoid process of wing of atlas.  
**Action:** - Same as the proceeding.
- 2. Complexus:** - This muscle covers the ligamentum nuchae.  
**Origin:**-Spines of the 2<sup>nd</sup>, 3<sup>rd</sup> and 4<sup>th</sup> thoracic vertebrae, transverse process of T1,- T10 vertebrae and the articular process of the L2 – C7 vertebrae.  
**Insertion:**-Occipital bone lateral to the insertion of the ligamentum nuchae Mastoid process of wing of atlas.  
**Action:** - Chief extensor of the head and to incline it laterally.
- 3. Multifidus cervicis:**-This muscle made up the oblique bundles which are placed over the dorsal surface of arches of the last five vertebrae.  
**Origin:** - Posterior articular process of the last- five cervical vertebrae.  
**Insertion:**- The spines and articular process of the cervical vertebrae.  
**Action:** - Extends the head or flex it laterally.
- 10. Obliquus capitis posterior:** - It is a quadrilateral muscle situated chiefly over the wing of atlas and axis.  
**Origin:** - posterior oblique process and spine of the axis.  
**Insertion:** -Dorsal face of the wing of atlas.  
**Action:** - To rotate the atlas and with it to rotate the head to one side.
- 11. Obliquecapitis anterior:** - This is also a quadrilateral muscle situated on the side of the occipitoatlantal joint.  
**Origin:** - Anterior edge and ventral surface of the wing of atlas.  
**Insertion:**-Paramastoid and mastoid processes.  
**Action:** - To extend the head on the atlas and flex the head to a side.
- 12. Rectus capitis domalis major:-** It extends from the axis to the occipital bone along the dorsal median line.  
**Origin:** - Spine of axis.  
**Insertion:** - Occipital bone, near the external occipital protuberance.  
**Action:** - To extend the head.

**13. Rectus capitis dorsalis Minor:** - This muscle lies under the preceding muscle.

**Origin:-** Dorsal arch of the atlas.

**Insertion:-** Occipital bone, between the external occipital protuberance and foramen magnum.

**EXERCISE** Draw a well labelled diagram of muscles of neck region.

## Practical No. 6

### Dissection/demonstration of tunics of eye

The organ of sight is the **eyeball** and its **accessories** (accessory structures e.g. ocular sheath, ocular muscles, eyelids, conjunctiva and lacrimal apparatus).

**1. Ocular sheath/Periorbita:** It is dense fibrous membrane lining the orbit which encloses the structures contained in the orbit. It is narrow behind and wide in front. It is lined over by extra orbital fat. It is attached along with optic foramen posteriorly whereas lodged into orbital rim.

**2. Ocular muscles:** There are four rectus muscles, two oblique muscles and one retractor muscle.

S. N.	Name of muscle	Origin	Insertion	Action	Nerve supply
1.	Dorsal rectus	Optic foramen	Anterior part of eye ball sclera	Elevate eye ball	Oculomotor
2.	Ventral rectus	- Do -	- Do -	Depress eye ball	- Do -
3.	Medial rectus	- Do -	- Do -	Adduct eye ball	- Do -
4.	Lateral rectus	- Do -	- Do -	Abduct eye ball	Abducent
5.	Dorsal oblique	Near the ethmoidal foramen	Sclera between the dorsal and lateral recti muscles	To rotate the eye ball along a longitudinal axis. It raises the lateral edge of the pupil.	Trochlear
6.	Ventral oblique	Depression behind the lacrimal fossa	Into the sclera near the insertion point of the lateral rectus muscle. It is inserted to the sclera between the dorsal and lateral recti muscles.	To rotate the eye ball along a longitudinal axis. It raises the lateral edge of the pupil.	Oculomotor
8.	Retractor oculi	Around optic foramen	Posterior part of sclera	Retract eye ball	Abducent

**3. Eyelids:** These are two protective organs covering the anterior surface of eye which also helps to spread lacrimal fluid.

**Palpebral fissure:** It is the gap between upper and lower eyelid.

**Canthi/Angles:** The two ends at the junction of upper and lower eyelids are canthi. They are external (lateral) and internal (medial).

**4. Conjunctiva:** It is the mucous membrane of eye which covers the internal surface of eyelids and then reflected over sclera and cornea. It is divided into two parts - palpebral and bulbar. The point of reflection is **fornix conjunctiva**.

**Conjunctival sac:** It is formed between the palpebral and bulbar conjunctiva when the eyelids are closed.

**Third eyelid:** It is placed at the internal angle of eye between eyeball and orbit.

**5. Lacrimal apparatus:** The lacrimal apparatus consisting of the following structures.

a) **Lacrimal gland:** It is lodged in a depression on the under surface of supra-orbital process and placed on supero-external aspect of eyeball. It is serous gland which secretes the lacrimal fluid.

b) **Excretory duct:** These are 6 to 10 ducts which convey the lacrimal fluid and open by minute orifice on supero-external part of conjunctiva.

c) **Carunculolacrimalis:** It is a small rounded brown or red body situated in lacrimal lake. It directs the flow of tears towards puncta lacrimalis.

d) **Puncta lacrimalia:** These are two slit like openings situated one on each eyelid behind the internal angle of eye.

e) **Lacrimal canals:** These are two narrow short tubes, superior and inferior. These begins at puncta lacrimalia, converge and terminate in the lacrimal sac.

f) **Lacrimal sac:** It is a membranous pouch lodged in the lacrimal fossa which acts as reservoir for the lacrimal canals.

g) **Naso lacrimal duct:** It begins at the bottom of lacrimal sac. It passes down the osseous groove on the internal face of superior maxillary bone and opens in the nostrils.

**6. Eye ball:** It consists of three concentric tunics or coats within which three refractive media are enclosed.

**A) Fibrous tunic:** It is external coat and composed of an opaque posterior four fifth part, **sclera** and transparent anterior one fifth part, **cornea**.

**Sclera:** It is dense fibrous membrane which maintain the form of the globe.

**Lamina fusca:** It is a layer of delicate connective tissue on the internal surface of sclera which is attached to the choroid by this layer.

**Lamina cribrosa:** The fibers of the optic nerve piercing it a little below and external to the posterior pole gives a sieve appearance termed lamina cribrosa.

**Limbus:** It is the corneo-scleral junction. It is anterior transparent non vascular colourless convex part. The layers of cornea are:

1. Epithelium
2. Bowman's membrane (anterior limiting)
3. Substantia propria
4. Descemet's membrane (posterior limiting)
5. Endothelium or posterior epithelium

**B) Vascular or uveal coat:** It lies within the sclera, and consists of choroid, ciliary body and iris.

**Choroid:** It is the thin membrane between sclera and retina. The layers are as follows:

1. Lamina supra chorioidea
2. Lamina propria (a) Tunica vasculosa (b) Lamina chorio-capillaris
3. Lamina basalis

**Tapetumlucidum:** Near the entrance of optic nerve the choroid has a peculiar metallic luster owing to its shading from a brilliant green to blue called tapetumlucidum.

**Ciliary body:** It is the middle part of vascular coat which connects the choroid with periphery of iris. It consists of ciliary ring, ciliary muscle and ciliary processes. Zonular ligaments arise from the ciliary processes which holds the crystalline lens.

**Iris:** It is a muscular diaphragm placed in front of lens and visible through the cornea. It is pierced centrally by an elliptical opening known as pupil.

**C) Nervine coat (Retina):** It is a nervous tunic of eyeball which is delicate membrane extends from entrance of optic nerve to the margin of pupil.

- Layers of retina:**
1. Internal limiting membrane.
  2. Layer of optic nerve fibers.
  3. Ganglionic layer or layer of optic nerve cell.
  4. Inner molecular or synapse layer.
  5. Inner nuclear or layer of inner granules
  6. Outer molecular or synapse layer
  7. Outer nuclear layer
  8. Layer of rods and cones
  9. External limiting membranes
  10. Pigmented layer

**Refractive media:**

1. **Anterior chamber:** It is the space bound in front by the cornea and behind by the anterior face of the iris and central part of the lens
2. **Posterior chamber:** It is a narrow space bound in front by the posterior surface of the iris and ciliary processes behind.
3. **Aqueous humor:** It is a clear fluid of an alkaline reaction, consisting chiefly of water with a trace of albumin and chloride of sodium.
4. **Crystalline lens:** It is a biconvex transparent body situated behind and partly in contact with the posterior face of central part of the iris and in front of the vitreous humor.
5. **Vitreous humor:** It is a jelly like transparent substance which occupies the space between the lens and the retina. It is depressed in front to form the fossa hyaloidea for the lodgement of the lens. It's surface is covered by a delicate transparent membrane, the hyaloid membrane.

## Species differentiation:

### Horse:

- (i) Eye lids are thinner and more freely movable.
- (ii) Tarsal glands are superficially placed.
- (iii) Cartilage of third eyelid is elongated.
- (iv) Lacrimal gland is thinner and flatter, oval in outline.
- (v) Excretory ducts are short, 12 to 15 in number.
- (vi) Eyeball is larger than ox otherwise same.
- (vii) Cornea is thinner.
- (viii) The upper part of pupillary border of iris has black mass in middle known as **granulairidis**.

### Dog:

- (i) Orbital rim is incomplete and completed by orbital ligament.
- (ii) Palpebral fissure is elliptical in outline.
- (iii) Lacus lacrimalis is shallower and carunculalacrimalis is smaller.
- (iv) Cartilage of third eyelid is nearly triangular. It's deeper part is surrounded by a reddish glandular mass called as **gland of third eyelid**.
- (v) Lacrimal gland lies under orbital ligament and is flat.
- (vi) Eye ball is more spherical.
- (vii) Anterior part of sclera and cornea is almost circular.
- (viii) Tapetum of choroid is nearly triangular or crescentic area. It has metallic lusture and is often golden colour shading to blue.
- (ix) The ciliary muscle is better developed.
- (x) The iris is yellowish brown in colour.

### Pig:

- (i) Eye ball do not protrude from orbit.
- (ii) Eye lids are relatively thick and less movable.
- (iii) Tarsal glands (Meibomian) are well developed.
- (iv) Sweat glands are more in eyelid.
- (v) Third eyelid is T shaped (anchor shaped) and covered by nictitating membrane.
- (vi) Pig also posses Harderian (deep) and superficial gland.
- (vii) Lacrimal gland is small.
- (viii) Sclera is highly pigmented with dark hair coat and white in less coloured pigs.
- (ix) Cornea is oval and limbus is not distinct.
- (x) Tapetum lucidum is absent.
- (xi) Pupil is oval.
- (xii) Retina is diurnal type.

**Fowl:**

- (i) Lower eyelid is better developed and more mobile than upper one.
- (ii) Third eyelid is well developed.
- (iii) Gland of third eyelid is better developed and larger than lacrimal gland.
- (iv) Tarsal glands are absent.
- (iv) Eye ball is large and slightly movable.
- (v) Orbital rim is incomplete.
- (vii) Right and left orbital cavities are separated by inter orbital septum.
- (viii) Sclera has hyaline cartilage between two fibrous layers.
- (ix) Posterior cartilaginous portion at posterior part is ossified to form posterior sclerotal ring at entrance of optic nerve.

**Anterior sclerotic ring** is formed at junction of sclera and cornea, composed of bony scales which can move on each other.

- (x) **Pecten:** a vascular, pigmented membrane structure, folded like fan which extends from point of entrance of the optic nerve to the vitreous humour, sometimes even forwards to the capsule of the lens. This structure is considered as a part of chorioid.
- (xi) The pupil is round.
- (xii) Iris is yellow, it may be dark or red.
- (xiii) Lens is flat on its anterior face.

**Corneal reflex:** Due to presence of motor neuron endings on surface of cornea whenever any particle comes in contact with cornea. These nerve endings get stimulated so blinking starts to protect eye ball.

**EXERCISE**

Draw a well labelled diagram of eye in cattle.





## Practical No. 7

### Study of teeth, tongue, pharynx, thyroid, parathyroid and salivary glands and differences in horse, dog, pig and fowl

#### TEETH

The teeth are hard, dense, white or yellowish white structure implanted in the alveoli and projecting into the mouth. They are the organs of prehension, mastication and sometimes defence. They are either *temporary*, milk or deciduous, present in early life or, *permanent*, which replaces the temporary ones. The teeth are classified according to their form and position as *incisors*, *canines* and *molars*.

The part of the tooth covered with enamel and seen above the gum is the *crown* and *body*. The part of tooth which is placed inside the gum and is fixed in the alveolus is called *fang* or *root*. The line of junction between the crown and the fang is called *neck*. The surface of a tooth apposed to the one next to it is the contact surface and that which comes in contact with the tooth of the opposite jaw is the table on the *grinding surface*. The surface of the tooth facing towards the lip is the labial surface, towards the tongue is the lingual surface and towards the cheek is the buccal surface.

#### Dental formulae:

Cattle	:	2(I 0/4 C 0/0, PM 3/3 and M 3/3)	= 32
Stallion	:	2(I 3/3, C 1/1, PM 3 or 4/3 and M 3/3)	= 40/42
Mare	:	2(I 3/3, C 0/0, PM 3/3 and M 3/3)	= 36
Dog	:	2(I 3/3, C 1/1, PM 4/4 and M 2/3)	= 42

**Teeth of cattle:** The upper incisors are absent. Eight lower incisors are arranged in a curved line, situated on the anterior part of the floor of the mouth. These teeth are movable as the size of the alveoli is bigger than the root that is attached to the periosteum of the alveoli. It presents shovel shaped crown. Infundibulum is absent. The crown is shorter than the root. The incisors are designated as *central*, *intermediated*, *lateral* and *corner* according to their position. Temporary incisors are smaller in size, white in colour and the crown is narrow. Canines are *absent* in cattle.

The cheek teeth (premolar and molars) are 24 in number six on each side of each jaw. The anterior three of these six teeth are premolars and the posterior teeth are molars. These are compound teeth with multiple roots marking double layer of enamel. The crown is generally four sided with a distinct neck. The masticatory surface of each upper and lower teeth presents an inclination. The cheek teeth except the first and the last are larger and quadrilateral. The first three cheek teeth have three roots and the next three have four roots. The lower teeth are narrower and slightly shorter than the upper ones.

**Blood supply:** Infra - orbital and the mandibulo-alveolar arteries for upper and lower teeth, respectively.

**Nerve supply:** Infra - orbital and the mandibular nerve which are the branches of trigeminal (5th cranial) nerve for upper and lower teeth, respectively.

**Species differentiation:**

**Horse:** There are six incisors in each jaw. The table of each incisor presents an infundibulum which helps in age determination. Roots of these teeth are firmly attached to the alveoli, thus restricting any movement. There are four canine teeth in male. Longitudinal groove present on the vestibular surface of upper corner incisor called Galvance groove. First premolar is generally absent. When it is present in reduced form, it is called wolf tooth.

**Dog:** Incisors are placed close together directing vertically. The upper incisors are more developed than the lower incisors. They correspond to an opposite tooth. The canines are large, conical and curved. The lower canine is close to the corner incisor. Upper 4th and lower 5th cheek teeth are larger than the rest and termed the carnassial or sectorial teeth.

**Fowl:** Teeth are absent.

**EXERCISE** Draw a well labelled diagram of section of a tooth.



## **TONGUE**

The tongue is the chief organ of prehension. It is highly protractile and very sensitive. It is located in the cavum oris above the floor of the mouth cavity between the two horizontal rami of mandible suspended by mylo-hyoid muscle and attached to the lingual process of the hyoid bone. It consists of a tip or apex, body or radix and a base of root. The tip or apex is the free part which is thin, narrow and pointed.

The body is the middle part of the tongue. It is crossed by a transverse groove situated at posterior half of the tongue, called *fossa linguae*, with a rounded and elevated structure behind, called the *torus linguae* or *lingual eminence*. The body is related ventrally to the genio-hyoid and mylo-hyoid muscles. The *dorsum linguae* is the dorsal surface of the body, which remains in contact with the hard palate above during resting state.

The root is the posterior part of the tongue attached to the lingual process of the hyoid bone below the hyo-glossus muscle. It is the thickest part of the tongue. The root presents a thick glosso-epiglottic fold through which it is attached to the base of the epiglottis.

The *filiform papillae* are fine projections present on the dorsum and the margin of the tip. The *fungiform papillae* are large and are scattered over the dorsum, their number being numerous on the lateral aspect of the tongue. They protrude outside the dorsum linguae. The *vallate* or *circumvallate papillae* are arranged in two rows. They are large and circular being surrounded by a circular furrow, the *cleft* or *moat*. Their number varies from 10 to 16 on each side. The mucous membrane of root of the tongue present on the either side of the glosso-epiglottic fold, a number of round lymphoid elevation, the lingual follicles. The lingual glands are the mucous glands which occur in the submucous tissue and between the bundles of muscular tissue. Fungiform and vallate papillae contain taste buds.

### **Muscles of the tongue**

Interinsicmusclesisomyo-glossus, the fibres of which run in all directions inside the tongue and blend with the extrinsic ones.

Extrinsic muscles of the tongue are

1. M. stylo-glossus: It retracts the tongue and inclines it laterally
2. M. hyo-glossus: It retracts and depresses the tongue
3. M. genio-glossus: It depresses the tongue
4. M. palato-glossus: It blends with the hyo-glossus and ends on the root of the tongue. It narrows the isthmus faucium.

**Blood supply:** Lingual and sublingual arteries

**Nerve supply:** Motor nerve supply by hypoglossal nerve (12th cranial nerve). Sensory nerve supply is by the lingual nerve which is a branch of trigeminal nerve (5th cranial nerve) for anterior two third of the tongue and posterior one third is supplied by glosso-pharyngeal nerve (9th cranial nerve)

### Species differentiation

**Horse:** The tongue is elongated the tip being *spatula shaped*. The body and root are narrow and it is pink in colour. Torus linguae is absent. Lingual papillae are less prominent. Tongue is not a prehensile organ as it is not so protractile as in cattle. Filiform papillae are not sharp. Conical horny papillae are absent. Fungiform papillae are less in number. Circumvallate papillae are two in number situated on either side, with an occasional third one. *Foliate papillae* are present on either side of the root near the posterior pillar of soft palate, which contain taste buds. Lenticular papillae are absent.

**Dog:** The tongue is very mobile, wide and thin anteriorly and narrow and thick posteriorly. It is red on deep pink in colour. The dorsum presents a median groove and numerous short, pointed papillae that are directed backwards. The dorsum of the root and lateral walls of isthmus faucium present longer conical papillae. Fungiform papillae are absent on the root. Vallate papillae are three on the left side and four on the right side. The ventral surface of the tongue presents a cord like structure called *lyssa*. Foliate papillae are present.

**Pig:** The apex of the tongue is rounded. The torus linguae is absent. The dorsum of the root presents numerous caudally directed sharp papillae. Filiform papillae are a well developed glosso-epiglottic fold. Foliate papillae are present.

**Fowl:** The tongue is narrow, rigid and triangular with a fixed base and considerably free anterior part. It is attached to a well developed hyoid bone. There is a median groove on the dorsal surface rostrally. The apex is pointed at the tip, the root of the tongue being crossed by a row of pointed horny papillae directed caudally.

### EXERCISE

Draw a well labelled diagram of tongue of ruminants.



## **PHARYNX**

The pharynx is a musculo-membranous sac which is common to both digestive and respiratory passage. It is funnel shaped organ suspended obliquely downwards and backwards from the base of the cranium. It is placed behind the soft palate and attached by muscles to palatine, pterygoid and hyoid bone and also to cricoid and thyroid cartilages.

It is related dorsally to the base of cranium and supratharyngeal lymph node. Ventrally it is related to the larynx, laterally related with the internal pterygoid muscles, great cornu of the hyoid bone, external carotid and external maxillary artery, glosso-pharyngeal, anterior laryngeal and hypoglossal nerves, mandibular salivary gland and parapharyngeal lymph node.

### **Openings of the pharynx**

There are all together 7 orifices or openings of the pharynx through which it communicates with various structures. The pharynx communicates dorso-cranially with the nasal chamber by two openings called the posterior nares, cranio-ventrally with the cavum oris through the isthmus facium, ventrally with the laryngeal cavity through the opening of the larynx by adituslaryngis, caudally behind the opening of the larynx with the oesophagus through the aditusoesophagi and caudo-laterally with the Eustachian tubes by two slit like openings.

**Pharyngeal muscles:** They form the wall of the pharynx

1. M. Palatopharyngeus: It shortens the pharynx, larynx and oesophagus towards the root of tongue during the time of swallowing.
2. M. Pterygo-pharyngeus: Same as above
3. M. Hy-pharyngeus: It is a constrictor of the pharynx
4. M. Thyro-pharyngus: Same as above
5. M. crico-pharyngeus: Same as above.
6. M. Aryteno-pharyngeus: It is a small muscular band
7. M. Stylo-pharyngeus: It is a dilator of the pharynx

**Blood supply:** Common carotid, occipital, external maxillary arteries

**Nerve supply:** Glossopharyngeal (9th), Trigeminal (5th) and vagus (10th) nerves.

### **Species differentiation**

**Horse:** It is narrower and longer than ox. The aditusoesophagi is much smaller, but the posterior nares are larger. The dorsal wall of the pharynx is also related to the guttural pouches. The pharynx has a thin mucous membrane.

**Dog:** The pharynx is long and reaches the second cervical vertebra. The eustachian orifices are small and slit like. aditusoesophagi is small.

**Pig:** It is also long and narrow reaching the second cervical vertebra. It is divided into oro and naso pharynx which are connected by the narrow intrapharyngeal opening.

**Fowl:** The roof present a median slit which is common for the Eustachian tubes. The oropharynx is situated behind this slit which is extensive. The adituslaryngis is situated on the floor. The soft palate is absent.

## **SALIVARY GLANDS**

There are three pairs of salivary glands which open into the mouth. The total saliva produced by these glands is approximately 50 litres/day.

### **1. Parotid salivary gland:**

It is located on the side of the face, immediately below the base of ear in between posterior border of the ramus of the mandible and the wing of atlas, extending from the zygomatic arch to the angle of the mandible. It is purely a serous gland. It is reddish brown in colour and weighs about 120 g. It is irregularly quadrilateral in form. It presents two surfaces and three borders. The dorsal border is thick and embraces the base of the external ear. The anterior border is irregularly convex which is closely attached to the masseter muscle. The posterior border is slightly convex in its upper part and nearly straight in its rest extent. The lateral surface is covered by parotid fascia and facial cutaneous muscles. The medial surface is related to the great cornu of the hyoid bone, masseter muscle, parotid lymph node, submaxillary salivary gland, digastric muscle and superficial temporal and transverse facial vessels. The parotid duct or Stenson's duct is formed by the union of several lobular ducts, leaves the gland at the inferior part of its medial surface, passes above the external maxillary vein and reaches the anterior part of the masseter muscle to which it pierces and opens in the buccal cavity at the level of upper fifth cheek tooth on the papilla salivaris.

**Blood supply:** Common carotid and external maxillary arteries.

**Nerve supply:** Branches of facial, trigeminal and sympathetic nerves

### **Species differentiation**

**Horse:** It is yellowish gray in colour and is the largest salivary gland weighing approximately 200-225gm. The internal or medial surface of the gland faces the guttural pouch. The apex embraces the base of the ear with the base located inferiorly which is related to the external maxillary vein. The Stenson's duct emerges from the anterior border at its inferior part about an inch above the external maxillary vein and opens on the papilla salivaris situated opposite to the upper third cheek tooth.

**Dog:** The parotid gland is very small and irregularly triangular in shape. The base is oriented upward with a notched dorsal border. The apex lies over the mandibular salivary gland. The Stenson's duct leaves the gland at the lower portion of the anterior border, crosses the masseter muscle to open on the papillae salivaris located opposite to the upper third cheek tooth. Small accessory gland may be present along the course of the duct.

**Pig:** The gland is large and distinctly triangular. Its dorsal angle does not reach the base of the ear. It is pale in colour, embedded in fat. The Stenson's duct arises from the deep face and opens on the cheek opposite to upper fourth or fifth cheek tooth. Several large parotid lymph nodes are attached to the deep face of this gland.



**b) Submaxillary or Mandibular salivary gland:**

It is the largest gland which is irregularly oval in shape. It is longer than the parotid salivary gland. It extends from the fossa atlantis to the body of the hyoid bone. It is pale yellow in colour. It is elongated and curved, the concavity being superior. The posterior part is covered by the ramus of the mandible. Its lateral surface is covered by the parotid salivary gland and the digastricus muscle, the medial surface being related to the atlantal lymph node, common carotid artery and the larynx. The dorsal border is concave, the middle part of which gives origin to the Mandibular duct or Wharton's duct. This duct runs forward crossing the digastricus and stylohyoid muscle under the genio-glossus muscle, then crosses the hypoglossal nerve and runs medial to the sublingual gland under the mucous membrane of the floor of mouth and joins with the duct of ventral part of sublingual gland to open on carunculusublingualis, opposite on slightly behind the level of the corner incisor tooth.

**Blood supply** : Occipital, external carotid and external maxillary arteries.

**Nerve supply** : Chorda tympani and sympathetic nerves.

**Species differentiation**

**Horse:** It is much smaller and narrower than the parotid salivary gland weighing approximately 45-60gm. The Wharton's duct opens on the carunculusublingualis opposite to the canine tooth.

**Dog:** It is larger than the parotid gland, yellowish in colour and rounded in appearance. The proximal part of the gland is covered by the parotid gland, the rest portion being located superficially. The Wharton's duct arises from the deep face of the gland and opens on the carunculusublingualis located in front of the frenum linguae, opposite the lower, first cheek tooth.

**Pig:** It is small reddish in colour and oval in outline, being covered by the parotid gland. Its superficial surface is marked by rounded prominences. The Wharton's duct opens near the frenum linguae, but there is no papilla.

**1. Sublingual salivary gland:**

It is located under the mucous membrane of the floor of the mouth between the horizontal ramus of mandible and the tongue. The superior part is very extensive from the anterior pillar of the soft palate to the mandibular symphysis. It is very thin and yellowish in colour. It discharges its secretion by numerous short ducts between the pointed, conical papillae arranged in a linear series on each side of the floor of the mouth cavity. The inferior part is shorter and thicker than the superior part-extending from the mandibular symphysis to the level of the third cheek tooth. It is pinkish in colour. The major duct either joins with Wharton's duct or opens separately on the side of carunculusublingualis.

**Blood supply** : Sublingual artery

**Nerve supply:** Inferior division of the trigeminal nerve (5th cranial nerve) and the sympathetic nerves

**Species differentiation:**

- Horse:** The gland extends from the mandibular symphysis to the fourth or fifth lower cheek tooth. It is single in number. Numerous ducts open on small papillae situated on the sublingual fold.
- Dog:** It consists of two parts - superior and inferior. The superior part is long and pours the secretion directly into the mouth through number of small, short ducts or join the inferior division. The inferior division is closely associated with the sub-maxillary gland. It has a singly duct which is larger and open at the side of the Wharton's duct or join it.
- Pig:** The caudal part of the gland is reddish yellow in colour. Most of the ducts from the caudal part join to form the major sublingual duct which opens near the Wharton's duct. The superior (rostral) part is much larger. From this part, 8-10 minor sublingual ducts convey the secretion to the floor of the mouth.
- Fowl:** There are several salivary glands in fowl. The ducts of maxillary, palatine, cranial lingual, submandibular and angular salivary glands open into the mouth, whereas the ducts of the sphenopterygoid, caudal lingual, caudal submandibular and laryngeal open into the pharynx.

**2. Zygomatic salivary gland:**

It is also known as orbital gland, situated under the zygomatic arch and masseter and temporalis muscles. It is related medially to the periorbita and blood vessels. It discharges its secretion into the mouth cavity by 3 or 4 ducts, which either singly or unitedly opens above the upper last cheek tooth. *This gland is presented only in dog.*

**EXERCISE** Draw a well labelled diagram of position of different salivary glands in ox and dog.



## **THYROID GLAND**

These are two dark colored glands situated at the ventro-lateral aspect of the junction of larynx and trachea. Both the glands are connected ventrally by isthmus at the level of **2<sup>nd</sup> tracheal ring**. Medial surface is related to cricoids cartilage and 1<sup>st</sup> 1-2 tracheal rings. Laterally it is related to muscles, carotid artery, internal jugular vein, vagus nerve and oesophagus.

**Blood supply:** Cranial and caudal thyroid arteries

**Nerve supply:** Sympathetic fibers from cervical ganglion and parasympathetic fibers from recurrent laryngeal nerve

In **horse**, these glands are situated on either side of the trachea and just behind the larynx. They are oval in shape and connected by isthmus.

In **dog**, they are oval-elongated and flat structures situated at the lateral aspect of 1<sup>st</sup> 6 tracheal cartilages. Caudal ends are generally connected by glandular isthmus. The isthmus is inconstant.

In **fowl**, these are two reddish-dark coloured round small bodies situated at the ventral aspect of the common carotid artery close to the thoracic inlet.

## **PARATHYROID GLAND**

These are four (2 cranial and 2 caudal) reddish yellow colored small bodies situated at variable positions, close to the thyroid gland. They may be closely associated with the thyroids. Generally cranial glands are located cranial to the thyroid glands and the caudal glands are located at the caudal edges of the corresponding thyroid gland.

**Blood supply:** Cranial and caudal thyroid arteries

**Nerve supply:** Sympathetic fibers from cervical ganglion

**EXERCISE** Draw a well labelled diagram of thyroid gland showing its relation with trachea.

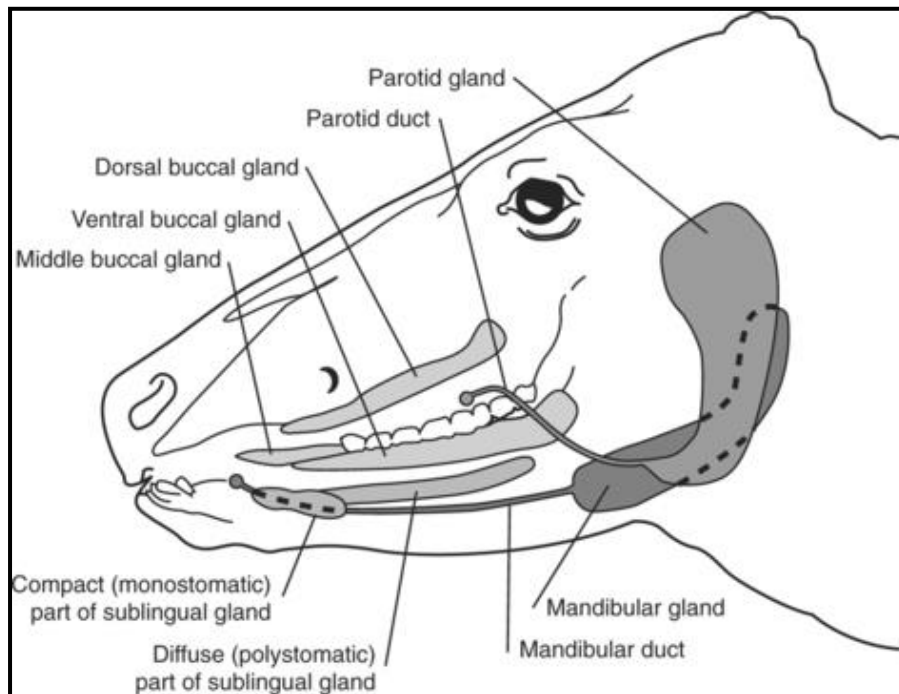


## Practical No. 8

### Surgical importance of Stenson's duct in domestic animals

#### Ligation of stenson's duct in bovine:

- **Indications-**
  - In persistent salivary fistula
  - To prevent excess salivation.
  - To bring about the atrophy of the gland
  - Experimental purpose
- **Anaesthesia & control:** Local infiltration in standing or recumbent position
- **Site** - Immediately in front of anterior border of the masseter muscle and about 1/2 to 1 inch above the inferior border of the horizontal ramus of the mandible where the duct can be palpated.
- **Surgical anatomy:** The duct of the parotid salivary gland (Stenson's duct) arises from the ventro-medial aspect of the gland and proceeds along the ventral and anterior borders of the masseter muscle to open into the vestibule of the mouth at the level of 5<sup>th</sup> upper cheek tooth through papilla salivalis. Anterior to masseter it is related to facial artery and vein in front.



**EXERCISE:** Write the course of Stenson's duct in cattle and opening of papilla salivalis in different domestic animals.



## Practical No. 9

### Study of cranial nerves

**There are twelve pairs of cranial nerves.**

- The first pair or **olfactory nerve** joins the convex ventral face of the olfactory bulbs.
- The second pair or **optic nerve** arises from the lateral geniculate bodies; the optic tracts converge to the optic chiasma and are then continued as optic nerves.
- The third pair or **oculomotor nerve** arises from the ventral face of the cerebral peduncle at the interpeduncular fossa.
- The fourth pair or **trochlear nerve** arises from the dorsal aspect behind the posterior colliculus of midbrain, pass outwards and emerge between the pons and the cerebral hemispheres.
- The fifth pair or **trigeminal nerve** is connected to the lateral part of the pons by a large sensory and a small motor root.
- The sixth pair or **abducent nerve** arises behind the pons lateral to the anterior ends of pyramids of the medulla.
- The seventh pair or **facial nerve** and the eighth or **auditory nerve** arise close together from the lateral part of corpus trapezoideum.
- The ninth pair or **glossopharyngeal nerve**
- Tenth and eleventh- **vagus nerve** and **spinal accessory nerve** arise in a series from the lateral aspect of the medulla behind the seventh. The spinal accessory nerve has two roots-a medullary and a spinal. A spinal root arises from the first five cervical segments of spinal cord and joins with the medullary root of spinal accessory nerve.
- The twelfth pair or **hypoglossal nerve** arise lateral to the posterior part of the pyramids of the medulla.



## Practical No. 10

### Study of blood vessels of head and neck region

The right and left common carotid arteries arise from the **bicarotid trunk** at the level of the thoracic inlet. They supply the head and the ventral structures of the neck.

The collateral branches of **common carotid** artery are

Arteries	Structures supplied
1. Muscular branches -	
2. Oesophageal and tracheal -	
3. Parotid branch -	
4. Thyroid branch -	
5. Thyro-laryngeal artery -	
6. Posterior meningeal artery -	

At the angle of mandible, below the ear there is carotid sinus at the level of digastricus. Here the common carotid artery trifurcates into **occipital, external maxillary and external carotid arteries**.

**Carotid sinus:** It is a thin walled dilatation of the terminal part of the common carotid artery at the originating points of the occipital and external carotid arteries. The nerves present in this sinus aid in regulation of blood pressure (baro-receptor).

**A. Occipital artery:** It passes upward and forward beneath the wing of atlas between the submaxillary salivary gland and rectus capitis ventralis major. It gives off the following branches in its course -

Arteries	Structures supplied
1. Muscular branches -	
2. Parapharyngeal branch -	
3. Pharyngeal branch -	
4. Posterior meningeal artery -	

The occipital artery then continued as the **condyloid artery** which enters in the condyloid foramen where it is in company with 12th cranial nerve and divides into anterior and posterior branches.

**B. External maxillary artery** (Lingo facial trunk): It passes downward and forward on the site of pharynx in company with the hypoglossal nerve. It becomes superficial by passing forward in the intermaxillary space. It reaches the ramus of lower jaw and comes on the external face where it is **convenient for feeling the pulse**. It then runs down ward and forward, and terminates in the structure of upper lip. The collateral branches are -

#### Arteries

#### Structures supplied

1. Pharyngo- palatine branch -
2. Parotid branch -
3. Lingual artery -
  - (a) Deep lingual artery
  - (b) Sub lingual artery
4. Facial artery
  - (a) Maxillary/superior labial artery -
  - (b) Mandibular/Inferior labial artery -

**C. External carotid artery:** It may be considered as the continuation of the **common carotid artery**. It passes ventrally upward on the great cornu, almost parallel to the posterior border of the vertical ramus of mandible and divides into **superficial temporal** and **internal maxillary arteries**.

(a) **Collateral branches** of external carotid artery are -

### Arteries

### Structures supplied

1. Pharyngeal branch -
2. Lingual artery -
3. A branch to submaxillary salivary gland -
4. Posterior auricular artery -
5. A branch to parotid salivary gland -
6. Pterygo-masseteric branch -

(b) **Superficial temporal artery:** It passes upward under the cover of the parotid gland. It again passes upward behind the temporo-maxillary articulation and emerges from the deep face of the parotid salivary gland. Further, it passes backward on the parieto-auricularis externus which arises in company with the lacrimal nerve then reaches the base of the horn core and divides into two terminal branches.

The collateral branches of **superficial temporal artery** are -

### Arteries

### Structures supplied

1. Anterior auricular artery -
2. Transverse facial artery -
3. Palpebral branches
4. Lacrimal branches
5. Temporal branches
6. Meningeal branch

7. Terminal branches

(a) Posterior or external large branch.

(b) Anterior or internal smaller branch.

(c) **Internal maxillary artery:** It originates about 2.5 cm below the temporo-maxillary articulation, passes obliquely forward and upward along the lateral aspect of the pharynx. It then crosses the external face of the lateral pterygoid muscle and reaches the inferior part of the temporal fossa. In the anterior part of its course, it lies in the lateral face of the medial pterygoid muscle. It divides at the maxillary hiatus, usually into two terminal branches, the **greater palatine** and **infraorbital branches**.

The collateral branches are

<b>Arteries</b>	<b>Structures supplied</b>
1. Pterygoid branches -	
2. Mandibular alveolar artery	
3. Middle meningeal artery -	
4. Deep temporal artery	
5. Ophthalmic artery	
6. Artery of rete mirabile cerebri	
7. Buccinator artery	
8. Infra orbital artery	
9. Greater palatine artery.	

**EXERCISE** Draw a well labelled diagram showing course of carotid artery with its main branches.

## Blood supply to brain and spinal cord

The brain is supplied by 3 major arterial components

- A. Rete mirabile cerebri :** The branches of internal maxillary artery, occipital artery and cranial branches of vertebral arteries form a fine vascular network or plexus at the floor of the cranial cavity around the sellaturcica.
- B. Emergent arteries:** They are two-**right** and **left**. These are the major vessels supplying the brain. They arise from the dorsal surface of the rete mirabile cerebri and immediately divides into **anterior** and **posterior** branches.
- C. Circulus arteriosus or circle of Wills:** It lies near the ventral surface of the brain. It is formed by the union of the anterior and posterior branches of the **emergent arteries**. Various important arteries supplying the brain arise from this circle. They are:
- 1. Anterior cerebral arteries:** These are paired arteries arising from the anterior part of the circle. They supply the cerebral hemispheres.
  - 2. Middle cerebral artery:** It is a single artery arising from the lateral part of the circle and supplies the cerebral hemispheres.
  - 3. Posterior cerebral arteries:** They are two in number, which arise from the lateral part of the circle of Wills.
  - 4. Anterior cerebellar artery:** Arise from the posterior part of the circle. It supplies the anterior surface of the cerebellum.
  - 5. Basilar artery:** It is a single artery which arises from the circle near the pons and medulla oblongata. It lies in the medial fissure and joins the **ventral spinal artery**.
  - 6. Posterior cerebellar artery:** It arises from the basilar artery at the posterior margin of the pons. It supplies the posterior surface of the cerebellum.
  - 7. Medullary arteries:** These are a number of arteries which arise from the basilar artery at right angles. They supply the ventral surfaces of the medulla.

**Spinal cord:** The major artery supplying the spinal cord in the **ventral spinal artery** which lies on the ventral surface of the spinal cord. The artery has a uniform diameter. Spinal branches of the vertebral, intercostal and lumbar arteries join the ventral spinal artery along its course.

**EXERCISE** Draw a well labelled diagram showing arterial supply to the brain.



## Practical No. 11

### Study of trachea and oesophagus

#### TRACHEA

The trachea is a non collapsable tube which continues the respiratory pathway from the cricoid cartilage of the larynx to the root of the lungs where it bifurcates to form the right and left principal branch at the level of the fifth thoracic vertebra just dorsal to the base of the heart. At the level of the third intercostal space, it gives an additional branches for the apical lobe of the right lung. The trachea consists of 48 to 60 hyaline cartilagenous C shaped rings. The length of the trachea is about 65 cm. The dorsal part of the cartilagenous plates is covered by trachialis smooth muscle. The trachea is more or less median in position except near its bifurcation, where it is pushed to the right by the aortic arch. The trachea can be divided into two parts cervical and thoracic parts.

**Cervical part:** It is related dorsally with the longus coli muscle except first posterior to the larynx where the oesophagus is situated. The oesophagus moves to the left-lateral side of the trachea at the level of the third or fourth cervical vertebra. Ventrally this part of trachea is related with the sterno-hyoideus muscle and isthmus of the thyroid gland, laterally to the common carotid artery, internal jugular vein vago-sympathetic trunk, recurrent laryngeal nerve, sternocephalics and one-hyoideus muscles, middle and posterior deep cervical lymph node and the lymphatics.

**Thoracic part:** The thoracic part lies in the anterior and middle mediastinum. Dorsally it is related with the longus coli muscle except near its bifurcation where it is related to oesophagus. It is ventrally related with brachiocephalic vein, anterior Vena cava, common brachiocephalic trunk, right common carotid and right pulmonary arteries, left recurrent laryngeal nerve and anterior mediastinal lymph node.

**Blood supply** : Branches of common carotid artery

**Nerve supply** : Vago-sympathetic trunk

#### **Species differentiation**

**Horse:** It is longer tube with a length of 30-32 inches and diameter of 2 to 2.5 inches. The tracheal rings are complete at cervical part, but incomplete in thoracic part. It does not have an additional branchial branch to right lung.

**Dog:** The trachea consists of 40-45 U shaped rings which are incomplete dorsally. It does not possess the apical branches.

**Pig:** The trachea possesses the apical branches for the right lung at the level of the 3rd rib.

**Fowl:** The trachea is 156 to 18 cm in length and consists of about 115 complete cartilagenous rings. At the bifurcation point of the trachea into two primary branches, a dilated portion exists on the trachea, called as **syrix**. It is voice producing organ.



**EXERCISE** Well labelled diagram of trachea of ox.

## **THE OESOPHAGUS**

The oesophagus is a musculo-membranous tube, which extends from the oropharynx to the stomach. Its length is about 0.75-1m with a diameter of about 50 mm. It consists of two parts - cervical part and thoracic part.

The **cervical part** begins at the pharynx in the median line behind the aortic arch dorsal to the anterior border of the cricoid cartilage, passes backwards and downwards on the dorsal surface of the trachea, till about the level of the third or fourth cervical vertebra. At this level (3 or 4 in cervical vertebra), it crosses the trachea obliquely, placing itself along the left side to the thoracic inlet.

The **thoracic part** starts at the level of the first rib and continues its course upto the level of second or third thoracic vertebra, where it again crosses the left face of the trachea obliquely upwards to gain its dorsal surface. It continues this dorsal relation of the trachea till the tracheal bifurcation. Then it passes through the middle mediastinum, and here, it is pushed to the right side of the aortic arch and lies to the right of the median line. It then passes upwards and backwards in the posterior mediastinum, inclines again to the left side and enters the hiatus oesophageus of the diaphragm. Coming through this cavity, it gains the abdominal cavity, and immediately terminates on the dome-like rumino-reticular wall at the cardiac orifice, a little left of the median line.

### **Relations of oesophagus:**

The cervical part is related dorsally to the straight muscles of head and longus coli muscle, ventrally related with the trachea and laterally with the common carotid artery, vago-sympathetic and recurrent laryngeal nerves.

The anterior mediastinal portion of the thoracic part of oesophagus is dorsally related with the longus coli muscle, ventrally with the trachea, vagus nerve on the right side and aortic arch and the thoracic duct on the left-side. The posterior mediastinal portion is related dorsally and ventrally with superior and inferior divisions of the oesophageal trunk of the vagus nerves, respectively.

**Blood supply :** Common carotid and oesophageal arteries

**Nerve supply :** Vagus (10th), recurrent laryngeal and sympathetic nerves.

## Species differentiation

- Horse:** The oesophagus is longer, narrow and less dilatable. It is approximately 1-1.2 meters in length. At its origin, it is related also to the guttural pouches. The oesophagus has cervical, thoracic and abdominal parts. The abdominal part is very short (2.5cm). The muscular coat of the oesophagus is striated up to the level of the base of the heart.
- Dog:** The oesophagus is relatively by wide and dilatable except at its origin. It forms constriction in the beginning due to the presence of thick submucosal gland at its ventral wall. The muscular wall of oesophagus is made entirely of striated muscle. The abdominal part is small.
- Pig:** The oesophagus is short and nearly straight. The abdominal terminal part of the oesophagus is flattened transversely. The muscular coat is striated except at the cardia. The oesophageal hiatus is a long slit in the right crus of the diaphragm.
- Fowl:** The wall of the oesophagus is thin with a wide lumen. The oesophagus dilates into a sac like structure near the thoracic inlet on the right side, called the crop or ingluvius or diverticulum. It serves as a temporary store house of food grains. The oesophagus has a small abdominal part which terminates in the proventriculus.

## Practical No. 12

### Study of nerve blocks of head

Regional nerve blocks are temporary blocking of pathway for passage of impulses by injecting local anaesthetic solution resulting in desensitization and paresis in the region. The successful regional nerve blocks require the thorough knowledge of anatomy of the particular region, course of nerve and the proper site of injection. The regional anaesthesia is not only used for surgical operations but also for diagnosis, prognosis, remove the pain, lameness due to chronic conditions and splints, ringbone, navicular disease, laminitis (Horse) etc.

#### Nerve blocks of head region-

**1. Cornual nerve block:** Cornual nerve is a sensory nerve supplying to the horn core and skin around its base. It is a branch of lacrimal nerve which is a division of the ophthalmic branch of trigeminal nerve (CLOT). The Cornual nerve emerges behind the orbit and ascends along frontal crest and placed relatively superficial in the upper third covered by skin and the thin layer of frontalis. The caudal part of the nerve is having close association with the superficial temporal artery.

**Indications-** Amputations of horn in certain conditions affecting the horn eg. horn cancer and fracture of horn.

**Site** - Close to frontal crest of the frontal bone about one inch below the base of horn.

In case of goat two site to block the cornual nerve - Behind the root of the supraorbital process to block the lacrimal branch and close to dorsal margin of the orbit to block the infra-trochlear branch.

**2. Mandibular nerve block:** The mandibular nerve is a branch of trigeminal and enters the mandibular foramen on the medial aspect of vertical ramus of the mandible and emerges through mental foramen on the lateral aspect of the mandible. During its course sensory branches are given off to teeth and gums of lower jaw.

**Indications** - To desensitize the cheek teeth, alveoli and gums of lower jaw.

**Site:** Cattle and Horse - At the mandibular foramen on the medial aspect of the vertical ramus. The Mandibular foramen is located at the intersection of two imaginary line passing along the masticatory surface of mandibular cheek teeth and perpendicular line running through the lateral canthus of the eye.

Dog- Mandibular foramen is located at the depression just in front of the angular process of mandible.

**3. Mental nerve block:** Mandibular nerve gains exit at the mental foramen on the lateral aspect of the horizontal ramus of the mandible.

**Indications** - To desensitize the lower lip.

**Site** - At the mental foramen on the lateral aspect of the horizontal ramus of the mandible near the body.

**Dog** - Mental foramen is located immediately below the root of second lower premolar tooth about ½ the distance between the dorsal and ventral border of the mandible.

**4. Maxillary nerve block:** The maxillary nerve which is a branch of the trigeminal nerve, is sensory in nature and emerges through the foramen orbitotundum, passes forwards in the pterygopalatine fossa and enters into infra-orbital canal through maxillary foramen. The maxillary nerve gives branches to the teeth of upper jaw.

**Indications** - To desensitize the teeth, alveoli and gums of upper jaw.

**Site** - The maxillary foramen to be reached by inoculation needle through the site 2 to 3 cm below the external canthus of the eye and between the posterior border of the malar bone and coronoid process of mandible.

**5. Infra-orbital nerve block:** Infra-orbital nerve is the continuation of maxillary nerve and emerges out through infra-orbital foramen just rostral to the facial tuberosity and dorsal to the first molar teeth.

**Indications** - Surgical interference with the upper lip and nostrils.

**Site-Cattle**-The infra-orbital foramen is reached through above the level of the upper third cheek tooth.

**Horse**- The infra-orbital foramen is reached through a line drawn between the naso-maxillary notch and the anterior end of facial crest. The middle of this line is located and a finger breadth towards the eye.

**6. Supra-orbital (Frontal) Nerve block:** Supra-orbital is one of the terminal branches of the ophthalmic division of the fifth cranial nerve. It is accompanied by the supraorbital artery and sensory to the upper eyelid.

**Indication** - To desensitize the upper eyelid.

**Site** - At the root of the supraorbital process.

**7. Orbital nerve block:** Ophthalmic and maxillary branches of trigeminal nerve are sensory in nature and emerge out from the cranium through foremen orbitotundum. The ophthalmic nerve supplies branches to the eye ball proper, eyelids, conjunctiva, lacrimal sac and third eyelid, while zygomatic branch of maxillary nerve supplies to skin of lower eyelid.

**Indication**- Evisceration of the eyeball, orbital abscesses, malignant diseases of eye

**Site**-Foramen orbitotundum reached through behind the middle of the supraorbital process in the temporal fossa.

**8. Retro-bulbar nerve block:** This block provides akinesia of the extra-ocular muscles by blocking cranial nerves II, III, and VI, thereby preventing movement of the globe.

**Indication** - Enucliation of the eye or for surgery of the cornea.

**Site** -The needle placement for retro-bulbar injection are the midway between medial and lateral canthus of eye or the upper and lower eyelids. The surgeon's finger is used to deflect the globe to protect it from the point of the needle.

**9. Auriculopalpebral nerve block:** Auriculopalpebral nerve supplies to the orbicularis oculi muscles it is the one of the branches of facial nerve and motor to eyelid and auricular muscle.

**Indication** - Surgical affection related to eyelid.

**Site** - At the level of the zygomatic arch.

**EXERCISE:** Well labelled diagram showing sites for different nerve blocks of head region in ox.

## Practical No. 13

### Surgical approach to guttural pouches – Viborg's triangle

Guttural pouches are large, auditory-tube diverticula that contain between 300 and 600 ml of air. They are present in odd-toed mammals. They are paired bilaterally just below the ears, behind the skull and connect to the nasopharynx.

Due to the general inaccessibility of the pouches in horses, they can be an area of infection by fungi and bacteria, and these infections can be extremely severe and hard to treat. The condition *guttural pouch tympany* affects several breeds, including the Arabian horse. The condition predisposes young horses to infection, often including severe swelling and often requires surgery to correct. The guttural pouch is also the site of infection in equine strangles.

The following are the important affections of the guttural pouches

- Guttural pouch tympany/ Tympanites
- Guttural pouch empyema/ Collection of pus in the guttural pouch
- Mycosis
- Neoplasia
- Cyst

### SURGICAL APPROACH OF THE GUTTURAL POUCH

**Indications:** An accumulation of pus or inflammatory exudates or rarely, food material in the pouch.

#### Preparation of patient:

- Administration of tetanus toxoid a week before surgery
- The operative area is prepared by shaving and application of an antiseptic before operation.

#### General Anaesthesia:

- Premedication with Acepromazine @ 0.02 - 0.05 mg / Kg
- Xylazine @ 0.5 to 1 mg / Kg
- Induction with ketamine @ 2.2mg /Kg
- Maintenance - Isoflurane

**Surgical procedure** - Hyvertebrotoomy Viborg's triangle

**Site of operation:** The antero-inferior border of the wing of the atlas.

#### Viborg's triangle:

An area bounded rostrally by the vertical border of the mandibular ramus, dorsally by the tendon of insertion of sternomandibularis muscle and ventrally by the linguofacial vein.

